



ORIGINAL RESEARCH PAPER

Dental Science

NON-SURGICAL ENDODONTIC MANAGEMENT OF NON-VITAL IMMATURE MAXILLARY INCISORS: A REPORT OF TWO CASES.

KEY WORDS: Apexification, MTA, Calcium hydroxide, Root canal therapy

Dr. Rachita Mehlawat*

PG Final year Department of Pedodontics and Preventive Dentistry, Inderprastha Dental College and Hospital, Sahibabad, Ghaziabad UP *Corresponding Author

Dr. Rishabh Kapoor

Senior Lecturer Department of Pedodontics and Preventive Dentistry, Inderprastha Dental College and Hospital, Sahibabad, Ghaziabad UP

ABSTRACT

Apexification is the standard treatment of choice for teeth with immature open apex and necrotic pulp. Two most widely employed materials in apexification are Calcium Hydroxide (CH) and Mineral Trioxide Aggregate (MTA). These materials differ in various physical, chemical and biological properties with variable results. Presented here are reports of two cases designed in a split mouth pattern in order to compare the results of CH and iodoform paste and MTA apexification in teeth having open apices and necrotic pulp owing to traumatic dental injuries. Results showed that MTA produces single appointment apical stop formation (24-48 hours) and faster resolution of periapical lesions as compared to CH and iodoform paste (14 months).

INTRODUCTION

The prevalence of Traumatic Dental Injuries in permanent anterior teeth in India varies from 7.3 to 8.79%.^{1,2} Anterior teeth are at the most susceptible position due to their projection. When the young anterior teeth with open root apex gets involved in traumatic dental injuries, the ensuing pupal necrosis often leads to arrest of normal process of apexogenesis. These teeth are often the candidates for apexification, a process that aims to induce hard calcified barrier at the root apex so that definitive root canal obturation can be achieved.³ Calcium hydroxide (CH) was previously the material of choice for apexification but it has some disadvantages like longer time taken for apical barrier formation, unpredictable results, higher probability of infections and root fractures on long term use by causing denaturation of dentinal proteins.⁴ Mineral Trioxide Aggregate (MTA) is progressively replacing CH apexification being a single-visit procedure and owing to its ability to induce cementogenesis and avoiding any reduction of fracture resistance of tooth roots even after long term use.⁵ It has superior sealing ability and more predictable results than CH, is more biocompatible, and has the ability to set even in presence of moisture and blood.⁶ The present article aims to report two cases where apexification was done using MTA and CH in a split mouth type study design.

CASE REPORTS

Case 1: A 14 year old male patient reported to the department with chief complaint of fractured and discoloured upper front teeth since 1 year. Trauma happened when the patient was 8 years old. Clinical examination revealed fractured #11 with discolouration. On radiographic examination, periapical radiolucency with open apices was evident in relation to #11 and #21. #11 showed a fracture line involving enamel, dentin and pulp of crown structure (Figure 1).

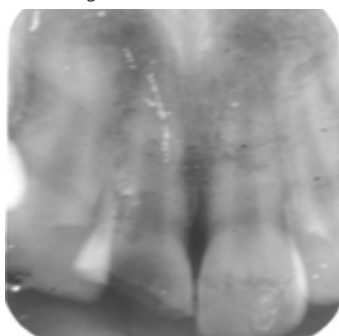


Figure 1: Pre-operative Radiograph

The involved teeth were non-vital, thus confirming the diagnosis of Ellis class IV fracture. Management of the involved teeth was done with apexification using MTA in #11 and CH premixed with iodoform paste (Metapex, Meta Biomed Co. Ltd, Korea) in #21. In

#11, a firm stop was observed in apical area of the root which allowed condensation of gutta-percha during obturation. On 1 year follow up, both teeth were asymptomatic and radiograph showed root end closure in relation to #11 but the apex was still open in relation to #21 with a period of follow up of 14 months (Figure 2). At the time of publishing this case report, #21 is still undergoing apexification.

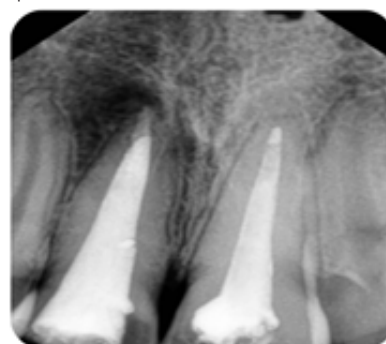

Figure 2: 14 Months follow up Radiograph

Case 2: A 12-year old male patient reported with chief complaint of swelling and pain in relation to upper anterior teeth. The patient had history of trauma 3 months back and was treated by a general dentist after the injury. Intra-Oral Periapical (IOPA) radiograph showed open apices of #11 and #21. #21 also showed a gutta-percha point extruding through the root apex. (Figure 3)

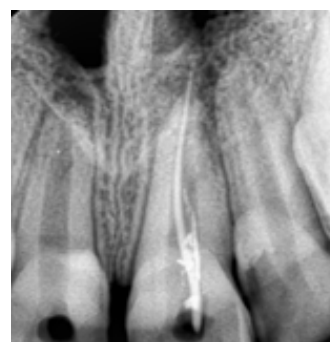

Figure 3: Pre-operative radiograph

Both teeth were non-vital and a diagnosis of Ellis class IV fracture was made. Endodontic management of teeth was done through apexification using MTA i.r.t. #21 and CH with iodoform paste i.r.t. #11. 2 months post-operative radiograph showed root end closure i.r.t. #21 with resolution of radiolucency while #11 showed partial resolution of radiolucency with root apex still open. At the

time of publishing this case report, #11 is also still undergoing apexification Figure 4).

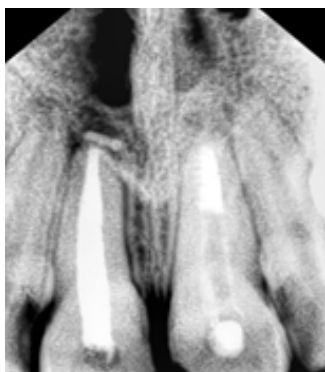


Figure 4: 2 months follow up radiograph

DISCUSSION

The traditional method of root end closure using CH with iodoform paste was favoured due to the antimicrobial and biological properties like its ability to induce hard tissue and reparative dentin formation.^{7,8} CH eliminates the micro-organisms by protein denaturation and damage to DNA. In addition to this, it also deactivates the toxic bacterial products.⁹ Despite so many advantages, CH has some inherent disadvantages like long duration of treatment for root end closure, less patient compliance, chances of re-infection, inconsistent sealing ability and root resorption.³ MTA has generated a lot of interest in the field of dentistry since its introduction in 1998.¹⁰ It consists of a mixture of Tricalcium aluminate, Tricalcium silicate, Silicate oxide and Tricalcium oxide. It has been used extensively in management of teeth involved in dental trauma. It has become popular as single visit apexification procedure in teeth having necrotic pulp with open apices. It has good handling property which results in ease in placement. Contrary to CH, MTA does not cause root resorption and neither gets resorbed. It is highly biocompatible and induces cementogenesis and periodontal ligament formation. High tissue pH of 10.5-12.5 induces hard tissue formation. It has significantly better sealing of canals as compared to CH, amalgam or Zinc oxide eugenol (ZOE).¹⁰ Cytotoxicity of MTA is also very low owing to which only minimal inflammation is encountered in event of extrusion beyond the apex. MTA is available in market in two forms: Gray and White MTA. Gray MTA has large particle size, longer setting time and higher compressive strength. It consists of ferrous oxide which imparts greyish discolouration to the tooth. Owing to this property, this material is not suitable for use in anterior teeth. White MTA on the other hand, consists of Magnesium oxide and hence does not cause any discolouration. This property makes it useful in apexification procedure of anterior teeth. In the present case, white MTA was used in anterior teeth. Results of apexification procedure were evaluated using Frank's criteria, which classifies results in four categories as follows:

- 1) Continued closure of canals and apex to a normal appearance,
- 2) Dome shaped apical closure with canal retaining a blunderbuss appearance,
- 3) No apparent radiographic change but a positive stop in the apical area, and
- 4) A positive stop and radiographic evidence of a barrier coronal to the anatomic apex of tooth.

The results showed a positive stop and radiographic evidence of a hard barrier coronal to the anatomic apex of tooth, in both the cases of MTA apexification similar to first criteria of Frank's classification of apexification, but in teeth treated by CH with iodoform paste, apexification, apices of both teeth were open at the time of follow up of 1 year 2 months and 2 months respectively. This goes in accordance with Sheehy et al¹¹ where the time range for apical end closure has been mentioned from 5-20 months. The authors did not observe any adverse complication in CH with iodoform paste treated teeth like infection, root

resorption or fracture, but the apices were still open at the time of follow up and the periapical lesions showed only partial resolution. This was in contrast to the MTA treated teeth where normal root end closure was seen with complete resolution of periapical lesions. Thus, the authors favour the use of MTA over CH with iodoform paste for apexification procedure in teeth with open apex and necrotic pulp.

REFERENCES:

- 1) Hegde R, Agrawal G. Prevalence of traumatic dental injuries to the permanent anterior teeth among 9- to 14-year old school children of Navi Mumbai (Kharghar-Belapur), India. *Int J Clin Pediatr Dent.* 2017;10(2):177-82.
- 2) Patel MC, Suján SG. The prevalence of traumatic dental injuries to permanent anterior teeth and its relation with predisposing risk factors among 8-13 years school children of Vadodra city: An epidemiological study. *J Indian Soc Pedod Prev Dent.* 2012;30:151-7.
- 3) Alhaddad B, Tarján I, Rózsa N. The Management of Crown Fracture of Immature Teeth by MTA and Calcium Hydroxide: Case Reports. *Dentistry* 2015; 5: 347.
- 4) Andreasen JO, Farik B, Munksgaard EC. Long term calcium hydroxide as a root canal may increase risk of root fracture. *Dent Traumatol.* 2002;18:134-7.
- 5) Rebecca L, Martin BS, Francesca M et al. Sealing properties of mineral trioxide aggregate orthograde apical plugs and root fillings in an in vitro apexification model. *J Endod.* 2007;33:272-275.
- 6) Muhamed AH, Azzaldeen A, Hanali AS. Mineral Trioxide Aggregate (MTA) in apexification. *Endodontology* 2013;25(2):97-101.
- 7) Asgary S, Akbari Kamrani F, Taheri S. Evaluation of antimicrobial effect of MTA, calcium hydroxide, and CEM cement. *Iran Endod J.* 2007; 2: 105-109.
- 8) Strom TA, Arora A, Osborn B, Karim N, Komabayashi T, et al. Endodontic release system for apexification with calcium hydroxide microspheres. *J Dent Res.* 2012; 91: 1055-1059.
- 9) Mohammadi Z, Dummer PM. Properties and applications of calcium hydroxide in endodontics and dental traumatology. *Int Endod J.* 2011; 44: 697-730.
- 10) Beslot-Neveu A, Bonte E, Baune B, Serreau R, Aissat F, et al. Mineral trioxide aggregate versus calcium hydroxide in apexification of non-vital immature teeth: study protocol for a randomized controlled trial. *Trials* 2011; 12: 174.
- 11) Sheehy EC, Roberts GJ. Use of calcium hydroxide for apical barrier formation and healing in non-vital immature permanent teeth: a review. *Br Dent J.* 1997; 183: 241-246.