



ORIGINAL RESEARCH PAPER

Dental Science

ORAL SUBMUCOUS FIBROSIS: TARGETING ETIOPATHOGENESIS

**KEY WORDS:** OSMF, gutka, betel nut, premalignant condition.

**Dr. Mamta Sharma**

Dental Surgeon, Dept of Oral Medicine & Radiology, Indira Gandhi Govt Dental College, Jammu.

**Dr. Mandeep Kaur\***

Assist. Prof, Dept of Oral Pathology & Microbiology, Indira Gandhi Govt Dental College, Jammu. \*Corresponding Author

**Dr. Suby Singh**

Registrar, Dept of Pathology. Govt Medical College, Jammu

ABSTRACT

Oral Submucous Fibrosis is one of the premalignant condition involving the oral cavity & pharynx. It is a chronic, progressive, scarring disease that predominantly affects the people in India and Southeast Asia. It predominantly occurs in the Indian subcontinent where the habit is more prevalent, so chewing of arecanut is an important factor in the aetiology of OSMF. Several factors such as chilli consumption, nutritional deficiency, genetic susceptibility, autoimmunity and collagen disorders have been suggested to be involved in the pathogenesis of this condition. The main aim of this presentation is to review the various factors involved in the etiopathogenesis of OSMF.

**Introduction**

OSMF is the most common oral precancerous condition with the unique prevalence in India and South East Asia, with an incidence rate ranging between 0.04% to 1.9%.<sup>1</sup>The diseases occurs mainly in Indians. It affects between 0.2% and 1.2% of urban population in India.<sup>2</sup>These cases have also been reported among Indians living in Kenya, Malaysia, Uganda, South Africa, Fiji Islands, and UK. Sporadic cases have been reported in other ethnic groups from countries such as Taiwan, Nepal, Thailand, South Vietnam, and Srilanka. Worldwide estimates in 1996 indicate that 2.5 million people are affected by the disease. In 2002, the statistics for OSMF from Indian subcontinent alone was about 5 million people.<sup>3</sup>

**ETIOPATHOGENESIS**

The etiology of OSMF still remains obscure. In past, many authors have proposed various hypothesis with a multifactorial origin for this particular condition.

'Quid' is defined as "a substance, or mixture of substances, placed in the mouth or chewed and remaining in contact with the mucosa, usually containing one or both of the two basic ingredients, tobacco and/or arecanut, in raw or any manufactured or processed form."<sup>3</sup> Recent epidemiological studies provide overwhelming evidence that areca nut is the main etiological factor for OSMF.<sup>4,5</sup>

It is the endosperm from the tropical tree 'Areca Catechu Linnaeus'. The fruit is orange yellow in color when ripe. The fibrous pericarp is removed from the seed or endosperm, which is then used fresh, after sun drying or in a crude form.<sup>5,7</sup>

Arecanut which is considered as predisposing factor mainly consists of<sup>4</sup>

- Tannins - Gallotannic acid, D.catechol
- Alkaloids - Arecoline, Arecaidine, Guvacine, Isoguvacine, Arecolidine, Guvacoline.
- Others – Fats, carbohydrates, proteins, and mineral matters.

The important flavonoid components of areca nut are tannins and catechins. Arecoline is the most abundant alkaloid. These alkaloids undergo nitrosation and give rise to N-nitrosamines, which might have a cytotoxic effect on cells.<sup>3</sup>

Arecoline has been demonstrated to promote collagen synthesis.<sup>3</sup> These chemicals appear to interfere with molecular processes of deposition and degradation of extracellular matrix molecules such as collagen.<sup>8</sup>

In India areca nut is chewed by itself, in the form of various areca nut preparations such as scented supari, mawa, manipuri tobacco,

pan masala, khaini, gutkha and in betel quid, either with or without tobacco.<sup>4</sup>

**Gutkha:** These are tobacco mixes containing arecanut, lime, catechu, and flavouring compounds. In India tobacco chewing has drastically increased in the last decade due to the easy availability of tobacco in small pouches or sachets named "Gutkha".<sup>4</sup>

**Pan** is betel leaf on to which slaked lime is smeared and this is wrapped over a mixture of betel nut and other additives such as tobacco powder, cardoman seeds, aniseed or gambeer (acacia catechu extract).<sup>2</sup> It is chewed slowly and is often kept in contact with the oral mucosa for several hours. Some authors have confirmed a positive association between betel nut chewing and onset of oral submucosal fibrosis.<sup>2</sup>

One of the best defined etiologic agents in the pathogenesis of most oral lesions, including OSMF, is tobacco, although it usually is associated with the areca nut making up the betel quid.<sup>4</sup> Tobacco is a plant whose leaves are used chiefly in making cigarettes and cigars. Other tobacco products includes smoking tobacco for pipes, chewing tobacco, and snuff. Tobacco contains small amounts of nicotine, a substance that acts as a stimulant on the heart and other organs. Nicotine also stimulates the nervous system, causing people to become addicted to it.<sup>9</sup>

Thousands of substances have been identified in Tobacco.<sup>10</sup>The type of carcinogen found in tobacco is N'-nitrosornicotine. N'-nitrosornicotine is produced by bacterial and enzymatic nitrosation of nicotine and can be found by reaction of salivary nitrates with nornicotine. N'-nitrosornicotine levels increased 44% when tobacco was mixed with saliva, and it is important to realize that the N'-nitrosornicotine extracted from chewing tobacco with saliva is approximately 1000 times that found in cigarette smoke. These findings have direct relevance to conditions such as OSMF because these patients have history of prolonged continuous tobacco chewing.<sup>11</sup>

**Sinor P.N. et al. (1990)**<sup>12</sup> conducted a case study in Bhavnagar, Gujarat to elucidate the etiology of OSMF. Totally 60 cases of OSMF were taken, among them 98% chewed areca nut in the form of mawa. It is a mixture containing mainly areca nut, some tobacco and lime paste. It was confirmed by their findings that areca nut as the most important etiological factor in OSMF. Their findings clearly demonstrated an increase in the relative risk with increase in the duration as well as frequency.

**Maher et al. (1994)**<sup>13</sup> a case-control study on chewing and smoking habits and oral Submucous fibrosis (OSMF) was undertaken in Karachi in 1989/90 it was found that areca nut had

the greatest role in the etiology of OSMF followed by pan and then pan with tobacco. It also appeared that the frequency and quantity of areca nut consumed was a more important factor than the duration of the habit.

**Murti P.R. et al. (1995)**<sup>4</sup> conducted epidemiological studies and have identified arecanut as the major etiologic agent also stated that the large quantities of tannins and the flavanoid catechin present in the arecanut do not appear to take part in collagen synthesis. However, they form cross linkages between the collagen peptide chain, inhibiting collagen degradation by collagenase and resulting in the accumulation of collagen in OSMF.

**Shah N. and Sharma P.P. (1998)**<sup>14</sup> in their study on 236 consecutive cases of OSMF it was found that chewing of areca nut/quid or pan masala (a commercial preparation of areca nuts, lime, catechu and undisclosed colouring, flavouring and sweetening agents) was directly related to OSMF.

**Tsai C.C. et al. (1999)**<sup>15</sup> in their study they hypothesized that betel nut alkaloids (arecoline, arecaidine) inhibit fibroblast phagocytosis and this provides a mechanism for the development of OSMF.

**Trivedy C.R. et al. (2000)**<sup>16</sup> in their study observed that copper was released from areca products during chewing and was deposited in oral tissues, they also found that lysyl oxidase activity was upregulated in OSMF. From these findings they hypothesized that, these cellular events lead to cross linking of collagen and elastin, making them less degradable. They suggested that an upregulation of lysyl oxidase in OSMF may be an important factor in the pathogenesis and progression of this disorder.

**Shah B., Lewis M. A. O., Bedi R. (2001)**<sup>17</sup> their paper highlights the link between oral submucous fibrosis and the regular use of areca-nut (paan) and the newer transcultural oral tobacco products.

**Yang Y.H. et al. (2005)**<sup>18</sup> studied the risk of areca/ betel quid chewing with or without cigarette smoking on oral submucous fibrosis and other oral mucosal lesions and reported a statistically significant association of oral mucosal lesions and OSMF with areca/betel quid chewing only.

**Saraswathi T.R. et al. (2006)**<sup>19</sup> conducted a cross-sectional study in South India to see the prevalence of oral lesions in relation to habits and concluded OSMF was most prevalent lesion among those who chewed panmasala or gutkha or betel quid with or without tobacco.

#### Chillies:

The frequent intolerance to spicy food, with chillies, and the vesiculation following the intake of food laced with chillies has led to hypothesis.

In wistar rats some connective tissue response akin to human submucous fibrosis on application of capsaicin an active principle of chillies has supported the aetiological role of chillies. The reaction was enhanced when the treatment was superimposed upon dietary protein or vitamin deficiency.

**Sami A.M., K.K. Chaubey et al. (2006)**<sup>20</sup> stated that chillies have an indirect effect on the pathogenesis of OSMF as hypersensitivity to chillies is the common factor in the development of OSMF as it causes chronic inflammation which leads to the formation of excessive fibrosis.

#### Nutrition deficiency:

Nutritional and vitamin deficiencies have been mentioned as possible aetiological factors. Mucosal changes similar to those in vitamin B and iron deficiency are seen in oral submucous fibrosis and seem analogous to sideropenic dysphagia.<sup>2</sup> Several investigators have reported anemia, vitamin, iron and protein deficiencies among OSMF patients. Iron metabolism is important in maintaining the health of the oral mucosa, and many disease

status, including cancer, are associated with iron deficiency.<sup>4</sup>

Because of the presence of iron deficiency anemia in patients of Malaysia, Ramanathan K.(1981)<sup>4</sup> hypothesized that this condition was an Asian version of sideropenic dysphagia where in the chronic deficiency leads to mucosal susceptibility to irritants such as chilli and areca nut use.

**Paissat D.K. (1981)**<sup>11</sup> stated that betel nut might initiate changes in the oral mucosa, which in the presence of protein or vitamin B deficiency and perhaps also chillies might promote the changes to OSMF.

**Daftary D.K. et al. (1993)**<sup>21</sup> in their study found a significantly higher frequency of Vitamin A, B, C and multiple vitamin deficiencies.

**Taneja L., Anjana B., Vaishali K. (2007)**<sup>22</sup> in their study haemoglobin levels were low in patients with oral submucous fibrosis suggestive of anemia. The normal maturation of the epithelium is dependent upon an iron-containing enzyme, cytochrome oxidase. In iron deficiency anemia, levels of this enzyme are low and a consequent atrophy of epithelium and lack of maturation results.

#### Immunologic and genetic predisposition:

An immunologic process is believed to play a role in the pathogenesis of OSMF. The increase in CD4 and cells with HLA-DR in OSMF tissues suggests that most lymphocytes are activated and that the number of Langerhans cells is increased. The presence of these immunocompetent cells and the high ratio of CD4 to CD8 in OSMF tissues suggest an ongoing cellular immune response that results in an imbalance of immunoregulation and an alteration in local tissue architecture.<sup>23</sup>

Activated macrophages can produce at least six fibrogenic cytokines, such as interleukin-1 (IL-1), tumour necrosis factor alpha TNF- $\alpha$ , interleukin-6 (IL-6), PDGF, and transforming growth factor beta (TGF- $\beta$ ). Activated T lymphocytes not only secrete fibrogenic cytokines that act directly on mesenchymal cells, but also produce other cytokines that in turn activate macrophages to secrete fibrogenic cytokines that modulate the function of mesenchymal cells indirectly. Cytokines and growth factors produced by inflammatory cells within the lesion may promote fibrosis by inducing proliferation of fibroblasts, upregulating collagen synthesis and downregulating collagenase production.<sup>24</sup>

In many autoimmune diseases, genetic factors are thought to be responsible for abnormalities in immunity. Immune response genes may be linked to the HLA-DR locus of the major histocompatibility complex in humans, and associations between this locus and autoimmune diseases has been sought.

**Jayanthi V. et al. (1992)**<sup>25</sup> observed in their immunological studies the raised values of IgA, IgE, and IgD while IgG and IgM are usually normal. Autoantibodies to gastric and parietal cells, as well as thyroid microsomal, antinuclear, reticulin, and anti-smooth muscle antibodies have been found in 65% of patients with the disease.

**Pillai R. et al. (1992)**<sup>26</sup> showed consistent immunologic abnormalities in patients with OSMF, which had been an implication for the malignant transformation of the lesion.

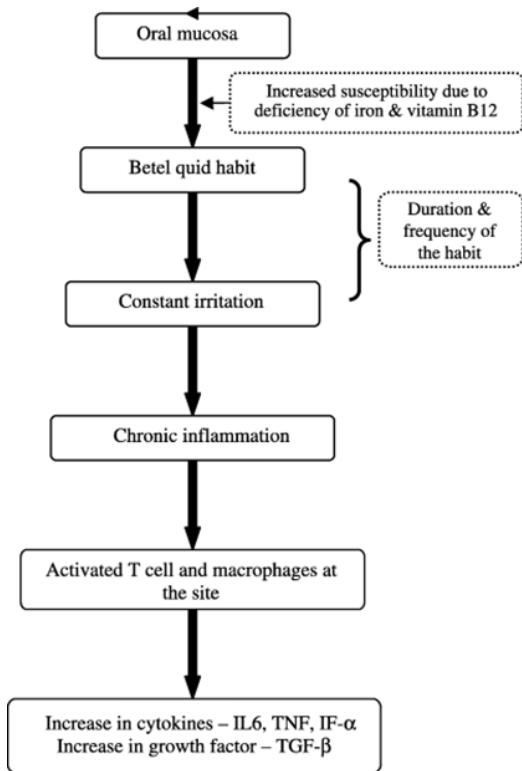
**Rajendran R. (1994)**<sup>27</sup> in his article stated that the complex constituents diffusing from tobacco mixtures, whether smoked or chewed either alone or in combination may be an important factor in the etiology of OSMF and there is clinical and experimental evidence on OSMF to support an autoimmune and increased evidence that immunoregulatory aberrations are primarily involved.

**Haque M.F. et al. (2000)**<sup>28</sup> have demonstrated increased levels of proinflammatory cytokines and reduced antifibrotic interferon gamma (IFN- $\gamma$ ) in patients with OSMF, which may be central to the pathogenesis of OSMF.

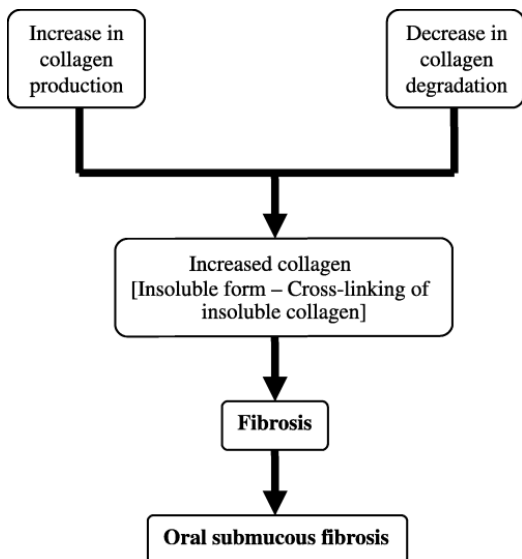
Chen H.M. et al. (2004)<sup>29</sup> in their study on 135 taiwanese patients with OSMF, lead to the conclusion that greater phenotype frequency of HLA-B76 and haplotype frequencies of HLA-B48/Cw7, -B51/Cw7 and -B62/CW7 patients are susceptible to OSMF.

P. Rajalalitha, S. Vali. (2005)<sup>30</sup>

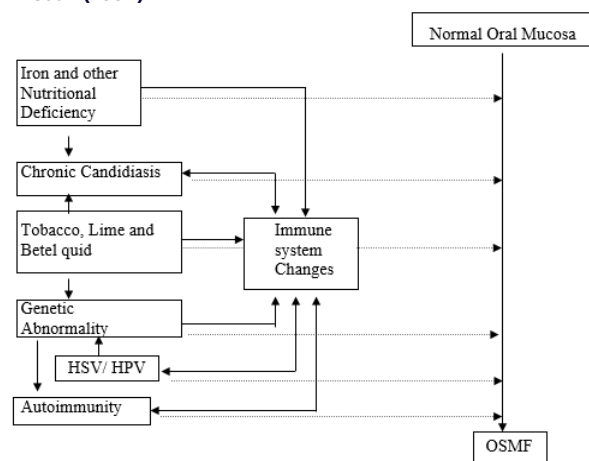
**Initial events of the disease process:** oral mucosa, which is in direct contact with BQ due to the habit, is the site of constant irritation. This results in a chronic inflammatory process characterized by the presence of inflammatory cells like T cells and macrophages. These cells release and/or stimulate the synthesis of various cytokines and growth factor. IL6: interleukin 6; TNF: tumor necrosis factor; IF- $\alpha$ : interferon alpha; TGF- $\beta$ : transforming growth factor-beta



**Overall effect of activated TGF- $\beta$  pathway:** There is an increase in collagen production and cross-linking (insoluble form) along with a decrease in collagen degradation. This produces an increased collagen deposition in the subepithelial connective tissue layer of the oral mucosa leading to OSMF.



**A multifactorial model for the pathogenesis of OSMF (Pillai R. et al. (1992)<sup>26</sup>**



- Bold arrows shows effects mediated by various factors through the immune system.
- Broken arrows show possible direct effects of the factors on oral mucosa.

**Bibliography**

1. Tupkari J.V., Bhavthankar J.D., Mandale M.S. Oral Submucous Fibrosis. A study of 101 cases. JIAOMR 2007; 19:02:311-318.
2. Jayanthi V., Robert C.S., Sher K.S., Mayberry J.F. Oral submucosal fibrosis a preventable disease. Gut. 1992; 33: 4-6.
3. P. Rajalalitha, S. Vali. Molecular pathogenesis of oral submucous fibrosis – a collagen metabolic disorder. Journal of Oral Pathology & Medicine. 2005;34:321-328.
4. Murti P.R., Bhonsle R.B., Gupta P.C., Daftary D.K., Pindborg J.J., Mehta F.S. Etiology of oral submucous fibrosis with special reference to the role of areca nut chewing. J Oral Path Med. 1995; 24:145-52.
5. Maher R., A.J. Lee, K.A.A.S. Warnakulasuriya, J.A. Lewis and N.W. Johnson: Role of areca nut in the causation of oral submucous fibrosis : a case control study in Pakistan. J Oral Pathol Med. 1994; 23: 65-69.
6. Vogt T.M., Mayne S.T., Graubard B.I., Swanson C.A., Sowell A.L., Schoenberg J.B., Swanson G.M., Greenberg R.S., Hoover R.N., Hayes R.B., Ziegler R.G. Serum Lycopene, other serum carotenoids, and risk of prostate cancer in US Blacks and Whites. Am J Epidemiol. 2002; 155: 1023–32.
7. Haque M. F., S. Meghji, R. Nazir and M. Harris: Interferon gamma (IFN- $\gamma$ ) may reverse oral submucous fibrosis. J Oral Pathol Med 2001; 30: 12-21.
8. Tilakarante W.M., Klinikowski M.F., Saku T., Peters T.J., Warnakulasuriya S. Review. Oral submucous fibrosis: Review on aetiology and pathogenesis. Oral Oncology. 2006; 42: 561-568.
9. The World Book Encyclopedia. 1993: 19.
10. Avon S.L. Oral mucosal lesions associated with use of quid. J Can Dent Assoc. 2004;70:244–8.
11. Paissat D.K. Oral submucous fibrosis. Int. J. Oral Surg. 1981; 10:307-31.
12. Sinor P. N., Gupta P. C., Murti P. R., Bhonsle R. B., Daftary D. K., Mehta F.S., and Pindborg J.J. A case-control study of oral submucous fibrosis with special reference to the etiologic role of areca nut. J Oral Pathol Med. 1990; 19:94-8.
13. Maher R., A.J. Lee, K.A.A.S. Warnakulasuriya, J.A. Lewis and N.W. Johnson: Role of areca nut in the causation of oral submucous fibrosis : a case control study in Pakistan. J Oral Pathol Med. 1994; 23: 65-69.
14. Shah N., Sharma P.P. Role of chewing and smoking habits in the etiology of oral submucous fibrosis (OSMF): a case-control study. J Oral Pathol Med. 1998; 27: 475–9.
15. Tsai C.C., R.H. Ma and T.Y. Shieh. Deficiency in collagen and fibronectin phagocytosis by human buccal mucosa fibroblasts in vitro as a possible mechanism for oral submucous fibrosis. J Oral Pathol Med. 1999; 28: 59-63.
16. Trivedy C.R., Warnakulasuriya K.A.A.S., Peters T.J., Hazarey V.K., Johnson N.W. Raised tissue copper levels in OSMF. Oral Path Med. 2000. 29: 24-8.
17. Shah B., Lewis M. A. O., Bedi R. case report Oral submucous fibrosis in a 11-year-old Bangladeshi girl living in the United Kingdom. British Dental Journal. 2001; 191: 130–132.
18. Yang Y.H., Lien Y.C., Ho P.S., Chen C.H., Chang J.S.F., Cheng T.C., Shieh T.Y. The effects of chewing areca/betel quid with and without cigarette smoking on oral submucous fibrosis and oral mucosal lesions. Oral Diseases. 2005; 11:88-94.
19. Gunaseelan R. Prevalence of oral lesions in relation to habits: Cross-sectional study in South India. Indian J Dent Res. 2006; 17: 121-5.
20. Sami A.M., Ali S.A., K.K. Chaubey. Original article: Epidemiological and etiological study of oral submucous fibrosis among gutkha chewers of Patna, Bihar. J Indian Soc Pedod Prev Dent. 2006; 24:84-9.
21. Daftary D.K., Murti P.R., Bhonsle R.B., Gupta P.C., Mehta F.S. and Pindborg J.J. Oral precancerous lesions and conditions of tropical interest in Oral Diseases in the Tropics, Prabhu S.R., D.F. Wilson, D.R. Daftary and N.W. Johnson (editors), chapter 36, Oxford University Press, Delhi, 1993: 417-422.
22. Taneja L., Anjana B., Vaishali K. Haemoglobin levels in patients with oral submucous fibrosis. JIAOMR 2007;19:2:329-333.
23. Lountzis N.I. Oral Submucous Fibrosis. Online Emedicine from webMD.
24. Tai Y. S., Liu B. Y., Wang J. T., Sun A., Kwan H. W., Chiang C. P. Oral administration of milk from cows immunized with human intestinal bacteria leads to significant improvements of symptoms and signs in patients with oral submucous fibrosis. J Oral Pathol Med 2001; 30: 618–25.
25. Jayanthi V., Robert C.S., Sher K.S., Mayberry J.F. Oral submucosal fibrosis a

- preventable disease. *Gut*. 1992; 33: 4-6.
26. Pillai R., P. Balam and K.S. Reddiar. Pathogenesis of oral submucous fibrosis. *Cancer*. 1992;69:2011-2020.
  27. Rajendran R. Oral Submucous Fibrosis: etiology, pathogenesis, and future research. *WHO bulletin OMS*. 1994; 72: 985-994
  28. Haque M. F., S. Meghji, R. Nazir and M. Harris: Interferon gamma (IFN- $\gamma$ ) may reverse oral submucous fibrosis. *J Oral Pathol Med* 2001; 30: 12-21.
  29. Chen H.M., Hseih R.P., Yang H., Kuo Y.S., Kuo M., Chiang C.P. HLA typing in Taiwanese patients with oral submucous fibrosis. *J Oral Pathol Med*. 2004; 33:191-9.
  30. P. Rajalalitha, S. Vali. Molecular pathogenesis of oral submucous fibrosis – a collagen metabolic disorder. *Journal of Oral Pathology & Medicine*. 2005;34:321-328.