



ORIGINAL RESEARCH PAPER

Anatomy

UNDIVIDED RETROMANDIBULAR VEIN AND ABSENT EXTERNAL JUGULAR VEIN-A CASE REPORT.

KEY WORDS: Retromandibular vein, anomalous vein, linguofacial venous trunk, common venous trunk.

Vandana Sharma* Department of Anatomy DR RPGMC Kangra at Tanda *Corresponding Author

Suman Yadav Department of Anatomy DR RPGMC Kangra at Tanda

ABSTRACT

The external jugular vein normally drains the scalp and face region of the body. However, various type of variations in the drainage system of head and neck may be there which are important from academic and clinical point of view During routine dissection of head and neck region in 80 years old male cadaver, a unilateral variation in the venous drainage system was observed on right side of neck. The right retromandibular vein had no divisions and it directly forms the common venous trunk with the linguofacial venous trunk and drains into the right internal jugular vein. The knowledge of such venous variations is of great concern to clinicians, surgeons, anaesthetists and radiologists who are dealing with this region.

Introduction: -

Normally the superficial temporal vein joins the maxillary vein in the substance of parotid gland to form the retromandibular vein. The external jugular vein then divides into two divisions. The anterior division of retromandibular vein unites with the facial vein to form the common facial vein which drains into the internal jugular vein. The posterior division of retromandibular vein unites with the posterior auricular vein to form the external jugular vein. The external jugular vein passes superficially to the sternocleidomastoid muscle and pierces the investing layer of deep cervical fascia just above the midpoint of the clavicle and drains into the subclavian vein. The external jugular vein receives blood from the scalp and face. (1)

Case report: -

During the routine dissection of the head and neck region in an 80 years old male cadaver in the department of anatomy DRPGMC, KANGRA AT TANDA, we observed multiple variations in the drainage pattern of the veins of neck on right side. In this case found that right retromandibular vein was unusually wide in calibre as compared to left, it received an anomalous vein just below its formation and remains undivided in its course. This undivided retromandibular vein joined the linguo-facial vein which was formed by the joining of facial vein and lingual vein at the anterior part of mandible. This common venous trunk then drained into the internal jugular vein There was complete absence of right external jugular vein and right posterior auricular vein

Discussion

The variations of superficial veins of head and neck are uncommon especially the variations of retromandibular is exceptional. (2,3) In our case we found not only the absence of right external jugular vein but also anomalous vein draining into the retromandibular vein, formation of linguo-facial trunk and undivided retromandibular forming a common venous trunk draining into internal jugular vein.

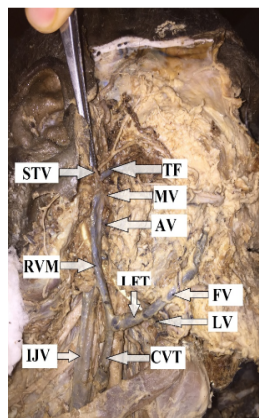


Figure-1

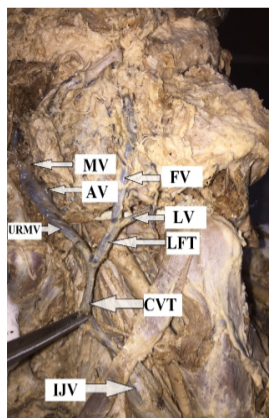


Figure-2

Fig-1&2 Dissection of neck showing variant venous drainage pattern. AV-anomalous vein, CVT-common venous trunk, FV-facial vein, IJV-internal jugular vein, LFV-linguofacial vein, MV-maxillary vein, RMV-retromandibular vein, URMV-undivided retromandibular vein STV-superficial temporal vein. In a study of 104 cases 1 case of undivided retromandibular vein draining into the internal jugular vein with absent common facial vein was reported. (7) In another case undivided retromandibular vein joining the facial vein to form the common venous trunk and draining into the subclavian vein and communication with the internal jugular vein was also reported. (8)

These variations and abnormal venous pattern results due to development defects during various stages of venous formation. Development of superficial veins of head and neck occurs immediately following skull development from superficial capillary venous plexuses during the embryonic period. It is a complex process which is initiated by formation and eventual regression of the cephalic veins which results in the formation of interconnecting venous spaces. With development, selective retention and regression of some network channels results in the definitive venous pattern. (4)

Linguofacial venous system develops from mesoderm of frontonasal and maxillary process. Retromandibular vein develops within the mesenchyme of temporal region and opens into linguofacial vein to form common facial vein which drains into internal jugular vein. External jugular vein develops from venous plexus in the neck region. (5,6)

Another case of undivided retromandibular vein and absent posterior auricular vein has been reported in which external jugular vein is communicated with the cephalic vein via large communicating vein. (9)

Absence of external jugular vein unilaterally or bilaterally which is a rare entity has also been reported. One case of bilateral absence of external jugular vein out of 25 cases has been reported. (10)

Absence of unilateral external jugular vein has also been reported in different studies. (11)

Retromandibular vein is used as a guide during the parotid and mandibular condylar surgeries, and external jugular vein is important for physicians and anaesthetist for assessing the central venous pressure for intensivists for central line cannulation etc.

Conclusion

Clinicians, surgeons, anaesthetists and radiologists who are dealing with this region need to be aware of such type of variations, which although uncommon but do exist, and should be kept in mind to avoid any intraoperative errors and complications.

References

1. Williams PL, Bannister LH, Berry MM, Collins P, Dyson M, Dussek JE, Ferguson MW. Gray's anatomy. 38th ed. New York: Churchill Livingstone Inc.; 1995. p.1576-80.
2. Bertha A, Suganthi R. Anatomical variations in termination of common facial vein. J Clin Diagn Res 2011; 5:24-7.
3. Balachandra N, Padmalatha K, Prakash BS, Ramesh BR. Variation of the veins of the head and neck: external jugular vein and facial vein. Int J Anat Var 2012; 5:99-101.
4. Pai M, Vadgaonkar R, Prabhu L, Shetty P. The different termination patterns of the facial vein: a cadaveric study. Firat Tip Dergisi 2008; 13:32-4.
5. Ghosh S, Mandal L, Roy S, Bandyopadhyay M. Two rare anatomical variations of external jugular vein – An embryological overview. Int J Morphol 2012;30(3):821-4.
6. Padget DH. The development of the cranial venous system in man: from the viewpoint of comparative anatomy. Contrib Embryol 1957; 247:79-153.
7. Mehra S, Kaul J M, Das S. Unusual venous drainage pattern of face: a case report. J Anat Soc India. 2003; 52: 6465.
8. Standring S, Ellis H, Healy JC, Johnson D, Williams A, Collins P, Wigley C. Gray's anatomy: the anatomical basis of clinical practice. 39th ed. Edinburgh: Churchill Livingstone; 2005. p.609- 18.
9. Nayak SB, Soumya KV. Abnormal formation Nayak SB, Soumya KV. Abnormal formation and communication of external jugular vein. Int J Anat Var. 2008;115–6.
10. Bertha A, Rabi S. Anatomical Variations In Termination of Common Facial Vein. J Clin Diagn Res 2011; 5: 24-7.
11. Abhinitha P, Rao MKG, Kumar N, Nayak SB, Ravindra SS, Aithal PA. Absence of the external jugular vein and an abnormal drainage pattern in the veins of the neck OA Anatomy 2013;1:15.