



ORIGINAL RESEARCH PAPER

Medicine

A RETROSPECTIVE STUDY TO ASSESS THE FUNCTIONAL OUTCOME OF ROTATOR CUFF PATHOLOGY MANAGED BY STEROID INJECTIONS

KEY WORDS: Functional Outcome, Prednisolone, Rotator Cuff, SPADI

Ajrawat S

Assistant Professor, Department of Orthopaedics, PIMS Medical College & Hospital, Jalandhar

Dr. Prabhjot Kaur*

Statistician Cum Tutor, Department of Community Medicine PIMS Medical College & Hospital, Jalandhar *Corresponding Author

ABSTRACT

Introduction: The present study aimed to assess functional outcome of rotator cuff pathology managed by steroid injections and to assess its associated complications. **Materials & Methods:** The study is a clinical, retrospective and observational study. A total of 50 patients who had undergone subacromial steroid injection for rotator cuff pathologies were included in this study. Data was collected from case sheets. Total duration of follow up was 6 months. While Clinical evaluation was done by SPADI scoring system. Data was analyzed by SPSS ver. 21.0 software. **Results:** Immediate Reduction in pain after steroid injection was seen in 74% cases while 26% cases had no reduction of pain. Significant reduction in pain during rest and activity was seen in cases at 6 weeks from baseline, which was maintained till 6 months (p<0.05). On clinical evaluation, a significant improvement was observed as per SPADI score, with scores at baseline was 59.4%, which improved to 84.6% at 6 weeks and to 89.3% at 6 months (p<0.05 for each follow up) (Table 3). Recurrence of pain was noted in 6 (12.0%) cases while re-tear rate in present study was 2 (4%) cases. As per patient's subjective assessment, 60% experienced good response after steroid injection while some improvement in symptoms was experienced in 28% cases. A total of 6 cases (12%) experienced no improvement after steroid injection. **Conclusion:** Subacromial injection of corticosteroids is an effective short-term therapy for the treatment of symptomatic rotator cuff. The use of such injections can substantially decrease pain and increase the range of motion of the shoulder. The incidence and severity of side-effects was also low.

INTRODUCTION

Rotator cuff pathologies are one of the most common injuries of the shoulder joint with a reported incidence rate ranging from 5 to 40%. It as a painful conditions that result from inflammation, damage, or both to the structures that lie within the subacromial space. The prevalence of rotator cuff pathology increases with age and it was also reported that there is an increase in the bilateral rotator cuff pathologies among patients over the age of 60 years. As the population continues to age, degenerative rotator cuff tears are likely to become an increasing problem [1,2].

Pain and subsequent dysfunction in the shoulder leads to disability, thus decreasing the quality of life. The consequent stiffness should be restored before surgical repair to optimize postoperative outcomes. A combination of physical therapy and corticosteroid injections (CSIs) are frequently used in conservative treatments and have been shown to relieve pain and to recover passive mobility in 80% of stiff shoulders within 12-16 weeks [3].

Corticosteroid injections (CSIs) directed to both intra- and peri-articular structures have been used for many years to relieve the symptoms of various shoulder conditions [4]. These injections are performed regularly by general practitioners, orthopaedic surgeons, physiotherapists and radiologists.

The physiological effects of local CSs are numerous [5]. Through their binding to cytoplasmic glucocorticoid receptors, CSs regulate the transcription of numerous pro- and anti-inflammatory proteins [6]. As a result of these properties, local injections of glucocorticoids have been advocated in the management of adhesive capsulitis, subacromial bursitis, subacromial impingement syndrome and supraspinatus tendonitis [7].

Despite widespread application in the clinical setting, the evidence supporting local CSI is equivocal [8-10]. As early as 1963, Quin and colleagues [8] reported that CSs and exercise therapy did not improve range of movement (ROM) or pain when compared with exercises alone. This limited efficacy is also reflected in more recent publications that have concluded that there is little reproducible evidence for the use of CSI in the management of shoulder pathology [9]. However, a recent systematic review on this topic acknowledged the poor methodological quality of studies previously reported that potentially account for these findings [10]. Furthermore, some studies demonstrated that CSIs could be effective to relieve persistent pain and to reduce stiffness after

rotator cuff repairs [11].

The benefits of CSIs must be balanced against their potential harms, reported in laboratory and animal studies. Whereas biopsy studies revealed that CSIs could reduce microvascularization at the rotator cuff footprint and decrease cell proliferation, other studies reported no deleterious effects [3]. The controversy led to more cautious use of CSIs in the clinical setting and the use of CSIs before or after rotator cuff repair therefore remains controversial in the absence of sizable comparative studies.

The present study was thus planned to assess functional outcome of rotator cuff pathology managed by steroid injections and to assess its associated complications.

MATERIALS AND METHODS

The study is a clinical, retrospective and observational study. All patients who had undergone subacromial steroid injection for rotator cuff pathologies were included in this study.

Sample size:

To test the mean change of 15 in SPADI score with 5% level of significance and 90% power, the same size of 50 is needed.

Calculation:

$$n = \frac{(Z_{1-\alpha/2} + Z_{1-\beta})^2 \sigma^2}{(d)^2}$$

The standard normal value for 5% level of significance, $Z_{1-\alpha/2} = 1.96$

The standard normal value for 90% power, $Z_{1-\beta} = 1.28$

The expected difference, $d = 15$

Pooled standard deviation, $\sigma = 25$

$$n = \frac{(1.96+1.28)^2 (25)^2}{(15)^2} = 49.61 \sim 50$$

Methodology

The complete data relevant to the study was collected from the case record forms. The data collected was transferred into a master chart which is subjected to statistical analysis by the biostatistician of our institution. Post procedural data was taken after 6 months of the steroid injection.

Inclusion Criteria

- Willingness to participate and follow up
- 18 year and over
- No history of significant shoulder trauma for example fracture, clinically suspected full thickness rotator cuff tear.

Exclusion criteria

- Below 18 year old
- Patients who lost follow up
- Those whose main complaint is due to neck problems, acromioclavicular pathology or other primary shoulder disorders including adhesive capsulitis or clinically suspected full thickness rotator cuff tear.
- Potentially serious pathologies like inflammatory arthritis, polymyalgia rheumatic, malignancy or ipsilateral shoulder surgery/replacement.
- Contraindications to local corticosteroid injection (known blood coagulation disorders, warfarin therapy).
- Inability to provide informed consent, complete written questionnaires.

Follow up Period: 6 months.

Outcome Variables: Clinical evaluation by SPADI scoring system.

Statistical Methods

Descriptive statistics for all qualitative variables was represented using frequency and percentage and for all quantitative variables assumption of normality was checked and if the assumption is not violated Mean (SD) was used else Median (IQR) was used to summarize it. SPADI score in different time periods was assessed using Pearson's correlation. If the SPADI score is normally distributed then parametric test like t-test and ANOVA was used to assess the relationship between SPADI score and qualitative variables else if the SPADI score was not normally distributed, non-parametric tests like Mann-Whitney U test and Kruskal Walli's test was used. For all the comparisons, p-value of less than 0.05 was considered for statistical significance.

RESULTS

Mean age of the study subjects was 50.32 years with 22% cases were over 60 years of age. Slight male predominance was seen in study group with 54% males to 46% females. Mean duration of symptoms was 2.12 years with 56% cases were symptomatic since less than one year. Pain was seen in 56% cases while stiffness and weakness in 24% and 16% cases. Inability to raise hand was seen in 16% cases (Table 1). Right side involvement was seen in 74% cases while left side involvement was seen in 26% cases. On MRI evaluation, partial tear was seen in 70% cases while complete tear was seen in 10% cases. Tendinosis was seen in 20% cases (Graph 1). Immediate Reduction in pain after steroid injection was seen in 74% cases while 26% cases had no reduction of pain. Significant reduction in pain during rest and activity was seen in cases at 6 weeks from baseline, which was maintained till 6 months (p<0.05) (Table 2). On clinical evaluation, a significant improvement was observed as per SPADI score, with scores at baseline was 59.4%, which improved to 84.6% at 6 weeks and to 89.3% at 6 months (p<0.05 for each follow up) (Table 3). Recurrence of pain was noted in 6 (12.0%) cases while re-tear rate in present study was 2 (4%) cases. One case of tendon rupture was also noted. As per patient's subjective assessment, 60% experienced good response after steroid injection while some improvement in symptoms was experienced in 28% cases. A total of 6 cases (12%) experienced no improvement after steroid injection.

DISCUSSION

A hospital based observational study was conducted with the aim of the assessing the functional outcome of rotator cuff pathologies managed by steroid injections. A total of 50 consecutive patients who underwent subacromial steroid injection for rotator cuff pathology were included in this study and were evaluated for short and mid term outcome.

Most of the subjects in Mean age of the study subjects was 50.32 years with 22% cases were over 60 years of age. Slight male predominance was seen in study group with 54% males to 46% females. Blair B et al. [12] in their study observed the mean age of

19 patients managed by subacromial injection of corticosteroids as 56 years with 12 males to 7 females. Average age in a study by McInerney JJ et al. [13] was 52 years with slight male predominance (10 males to 6 females). Dimitroulas T et al. [14] examined 60 consecutive patients who had undergone US examination and US-guided steroid injection. Average age was 64.4 ± 11.5 years and 42 were female. Baverel L et al. [15] in their study observed mean age of cases as 55.6 years with 53% males to 47% females.

Pain was seen in 56% cases while stiffness and weakness in 24% and 16% cases. Inability to raise hand was seen in 16% cases. Right side involvement was seen in 74% cases while left side involvement was seen in 26% cases. Pain and the stiffness was the common presenting feature in all of the studies and most of the authors observed predominantly right side involvement in rotator cuff pathologies [16-22].

Immediate Reduction in pain after steroid injection was seen in 74% cases while 26% cases had no reduction of pain. Significant reduction in pain during rest and activity was seen in cases at 6 weeks from baseline, which was maintained till 6 months (p<0.05). On clinical evaluation, a significant improvement was observed as per SPADI score, with scores at baseline was 59.4%, which improved to 84.6% at 6 weeks and to 89.3% at 6 months (p<0.05 for each follow up). As per patient's subjective assessment, 60% experienced good response after steroid injection while some improvement in symptoms was experienced in 28% cases. A total of 6 cases (12%) experienced no improvement after steroid injection.

Dimitroulas T et al. [14] in a similar study of 60 cases followed cases for 4 month after subacromial steroid injection. Thirty-four (56.6%) patients reported a good response, 13 (21.7%) some response and another 13 (21.7%) no response. Shin SJ et al. [22] in their study observed the mean (±SD) visual analog scale for pain (pVAS) score was 7.7 ± 1.2 at the time of the injection. This significantly decreased to 2.3 ± 1.4 at the end of the first month after the injection, demonstrating a 70.2% reduction in pain (p<0.01). At 3 months after the injection, the mean pVAS score was 1.2 ± 1.8. Agun K et al. [23] in their study also observed significant improvements from the baseline values in all pain and function parameters at the first and third month evaluation. Baverel L et al. [15] studied the role of corticosteroid injections (CSIs) in rotator cuff pathologies. A total of 212 cases were evaluated for a median of 2.9 years. The functional outcome as measured by constant scores improved significantly from 56.4 ± 15.1 to 80.8 ± 12.5. Coombes BK et al. [24] in a systemic review tried to establish clinical efficacy and risk of adverse events for treatment by injection in cases of tendinopathy. In pooled analysis of treatment for lateral epicondylalgia, corticosteroid injection had a large effect (defined as SMD>0.8) on reduction of pain compared with no intervention in the short term (SMD 1.44, 95% CI 1.17-1.71, p<0.0001). A systematic review assessing the value of physical therapy in the treatment of shoulder pain found some evidence to suggest that glucocorticoids may provide greater benefit compared with physiotherapy alone. Steroid injection may reduce pain, thereby enabling earlier participation in range of motion exercises and rehabilitation [16].

In present study, we observed a re-tear rate of 6%. Baverel L et al. [15] in their series observe the re-tear rate of 13% while Shin SJ et al. [22] observed the retear rate as 6.8%. Higher re-tear rates were observed in the studies by Park et al. [25] (25%) and Gwak et al. [26] (27%). The relatively lower retear rates in present study can be attributed to smaller follow up period of present study. Tendon rupture is a relatively rare complication observed in only one case in present study. Coombes BK et al. [24] in their study also observed only one (0.1%) case of tendon rupture. Similar results were seen by Baverel L et al. [15] and Shin SJ et al. [22]

CONCLUSION

Subacromial injection of corticosteroids is an effective short-term therapy for the treatment of symptomatic rotator cuff. The use of such injections can substantially decrease pain and increase the

range of motion of the shoulder. The incidence and severity of side-effects was also low. Thus subacromial corticosteroid injections in the acute or subacute phase provides additional short-term benefit without any complication when used together with nonsteroidal anti-inflammatory drugs (NSAIDs) and exercise.

TABLES

Table 1. Distribution of patients according to Presenting Complaints

Presenting Complaint	N	%
Pain	28	56%
Stiffness	12	24%
Weakness	8	16%
Inability to raise Hand	8	16%

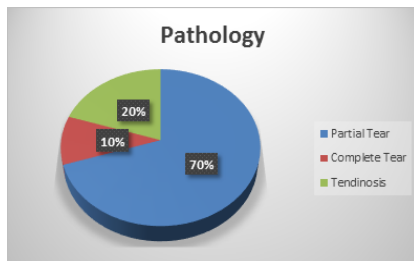
Table 2. Change in Mean VAS score over follow up period

VAS Score	baseline		6 weeks		6 months	
	Mean	SD	Mean	SD	Mean	SD
Rest Pain	4.3	1.6	1.0	0.8	0.8	0.7
Activity Pain	6.4	1.7	1.4	1.0	0.9	0.7
p- value	p<0.01 (Baseline vs 3 months)		p<0.01 (Baseline vs 6 months)			

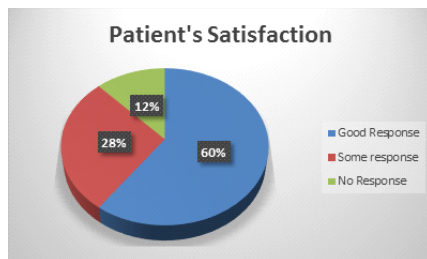
Table 3. Mean SPADI Score over follow up period

SPADI Score	Mean	SD
Baseline	59.4%	21.3%
6 weeks	84.6%	16.5%
6 months	89.3%	9.8%

Graph 1. Distribution of cases as per Incident pathology



Graph 2. Distribution of cases as per Patient's satisfaction



REFERENCES

- Mitchell, C., Adebajo, A., Hay, E., & Carr, A. (2005). Shoulder pain: diagnosis and management in primary care. *BMJ*, 331(7525), 1124-1128.
- Yamaguchi, K., Ditsios, K., Middleton, W. D., Hildebolt, C. F., Galatz, L. M., & Teefey, S. A. (2006). The demographic and morphological features of rotator cuff disease. A comparison of asymptomatic and symptomatic shoulders. *J Bone Joint Surg Am*, 88(8), 1699-1704.
- Baverel L, Boutsiadis A, Reynolds RJ, Saffarini M, Barthélémy R, Barth J. Do corticosteroid injections compromise rotator cuff tendon healing after arthroscopic repair?. *JSES Open Access*. 2017 Dec 19.
- Jones A, Regan M, Ledingham J et al. Importance of placement of intra-articular steroid injections. *BMJ* 1993; 307:1329.
- Lavelle W, Lavelle ED, Lavelle L. Intra-articular injections. *Anesthesiol Clin* 2007;25:85362.
- Barnes PJ. Anti-inflammatory actions of glucocorticoids: molecular mechanisms. *Clin Sci* 1998;94:55772.
- Tallia AF, Cardone DA. Diagnostic and therapeutic injection of the shoulder region. *Am Fam Physician* 2003;67: 12718.
- Quin CE. 'Frozen Shoulder' evaluation of treatment with hydrocortisone injections

- and exercises. *Ann Phys Med* 1963;8:229.
- van der Heijden GJ, van der Windt DA, Kleijnen J, Koes BW, Bouter LM. Steroid injections for shoulder disorders: a systematic review of randomised clinical trials. *Br J Gen Pract* 1996;46:30916.
- Buchbinder R, Green S, Youd JM. Corticosteroid injections for shoulder pain. *Cochrane Database Syst Rev* 2003;CD004016
- D.P. Huberty, J.D. Schoolfield, P.C. Brady, A.P. Vadala, P. Arrigoni, S.S. Burkhardt. Incidence and treatment of postoperative stiffness following arthroscopic rotator cuff repair. *Arthroscopy*, 25 (2009), pp. 880-890.
- Blair B, Rokito AS, Cuomo F, Jarolem K, Zuckerman JD: Efficacy of injections of corticosteroids for subacromial impingement syndrome. *J Bone Joint Surg Am* 1996;78: 1685-1689.
- McInerney JJ, Dias J, Durham S, Evans A: Randomised controlled trial of single, subacromial injection of methylprednisolone in patients with persistent, post-traumatic impingement of the shoulder. *Emerg Med J* 2003;20: 218-221.
- Dimitroulas T, Hirsch G, Kitas GD, Klocke R. Clinical outcome of ultrasound guided steroid injections for chronic shoulder pain. *International journal of rheumatic diseases*. 2013 Aug 1;16(4):398-402.
- Baverel L, Boutsiadis A, Reynolds RJ, Saffarini M, Barthélémy R, Barth J. Do corticosteroid injections compromise rotator cuff tendon healing after arthroscopic repair?. *JSES Open Access*. 2017 Dec 19.
- Green S, Buchbinder R, Glazier R, Forbes A. Interventions for shoulder pain. *Cochrane Database Syst Rev*. 1999;2.
- Buchbinder R, Green S, Youd JM. Corticosteroid injections for shoulder pain. *Cochrane Database Syst Rev* 2003; :CD004016.
- Koester MC, Dunn WR, Kuhn JE, Spindler KP. The efficacy of subacromial corticosteroid injection in the treatment of rotator cuff disease: A systematic review. *J Am Acad Orthop Surg* 2007; 15:3.
- Arroll B, Goodyear-Smith F. Corticosteroid injections for painful shoulder: a meta-analysis. *Br J Gen Pract* 2005; 55:224.
- Alvarez CM, Litchfield R, Jackowski D, et al. A prospective, double-blind, randomized clinical trial comparing subacromial injection of betamethasone and xylocaine to xylocaine alone in chronic rotator cuff tendinosis. *Am J Sports Med* 2005; 33:255.
- Sun Y, Chen J, Li H, Jiang J, Chen S. Steroid injection and nonsteroidal anti-inflammatory agents for shoulder pain: a PRISMA systematic review and meta-analysis of randomized controlled trials. *Medicine*. 2015 Dec;94(50).
- Shin SJ, Do NH, Lee J, Ko YW. Efficacy of a subacromial corticosteroid injection for persistent pain after arthroscopic rotator cuff repair. *The American journal of sports medicine*. 2016 Sep;44(9):2231-6.
- Akgun K, Birtane M, Akarimak U: Is local subacromial corticosteroid injection beneficial in subacromial impingement syndrome? *Clin Rheumatol* 2004;23:496-500.
- Coombes BK, Bisset L, Vicenzino B. Efficacy and safety of corticosteroid injections and other injections for management of tendinopathy: a systematic review of randomised controlled trials. *The Lancet*. 2010 Nov 20;376(9754):1751-67.
- J.Y. Park, S.H. Lee, K.S. Oh, S.G. Moon, J.T. Hwang. Clinical and ultrasonographic outcomes of arthroscopic suture bridge repair for massive rotator cuff tear. *Arthroscopy*, 29 (2013), pp. 280-289.
- H.C. Gwak, C.W. Kim, J.H. Kim, H.J. Choo, S.Y. Sagong, J. Shin. Delaminated rotator cuff tear: extension of delamination and cuff integrity after arthroscopic rotator cuff repair. *J Shoulder Elbow Surg*, 24 (2015), pp. 719-726.