ORIGINAL RESEARCH PAPER

Gynaecology

A CASE OF PRIMARY INFERTILITY: CONCEPTION FOLLOWING HYMENECTOMY FOR MICROPERFORATE HYMEN

KEY WORDS: Micro perforate hymen, Hymenectomy, Genital tract abnormality, Infertility

Dr. Navya S II-year MS OBGY, Department of Obstetrics and Gynaecology, NRI Academy of Medical Sciences, Guntur.

Dr. Prabhadevi K* Head of the Department, Department of Obstetrics and Gynaecology, NRI Academy of Medical Sciences, Guntur. *Corresponding Author

Dr.Srilakshmi B Associate Professor, Department of Obstetrics and Gynaecology, NRI Academy of Medical Sciences, Guntur.

ABSTRACT

Female genital tract abnormality is diverse and has varied presentations. Incomplete degeneration of the hymen occurs in 1:2000 live births. It is due to failure of canalisation of genital tubercle. Micro-perforate hymen is non-obstructive. The exact incidence is unknown. This is a rare case of micro perforate hymen where the patient presented with primary infertility, conceived after hymenectomy and delivered vaginally. A 25-year old nulligravida, presented to the OPD with primary infertility, normal secondary sexual characters and a membrane covering the vaginal introitus. Uterine sound could be passed through a pinpoint opening. USG was normal. 5 months after hymenectomy, patient reported at 14 weeks POG and she was delivered vaginally at term. Female congenital anomalies are uncommon but their impact on reproduction can be profound. Knowledge about this entity is required to make correct diagnosis and early detection. Correct surgical intervention is required for a better psychological and reproductive health.

INTRODUCTION

The female genital tract abnormalities are diverse and may have varied presentations. Incomplete degeneration of the central part of hymen leads to hymenal abnormality.[1] The incidence rates vary from 1 in 1000 to 1 in 10,000 females.[2] Hymenal anomalies may be imperforate which leads to hematocolpos and hematometra. Micro perforate hymen is non-obstructive, which may remain asymptomatic during the entire adolescence with no menstrual complaints. Due to paucity of literature on this entity it is difficult to comment on the true incidence. Here we present a rare case of micro perforate hymen where patient presented to us with primary infertility.

CASE REPORT

A 25-year old nulligravida, presented to the outpatient department anxious to conceive. She attained menarche at 14 years, has regular cycles with moderate flow and has been married for 3 years. The couple initially gave history of regular intercourse but on detailed inquiry they were found to have non-penetrative sex. On examination, she had normal secondary sexual characters. A membrane was seen covering the vaginal introitus, forming a blind pouch of about 2 cms length, with a pinpoint opening through which a uterine sound could be passed (Figure 1). On per rectal examination, uterus and cervix could be felt. Ultrasonogram was normal. She was subjected to hymenectomy (Figure 2 & 3) and the mucocutaneous junction was sutured with 3-0 Vicryl (Figure 4). Her postoperative period was uneventful and she was discharged on the 2nd post-operative day. She had regular follow-up. 5 months later patient reported at 14 weeks POG. She had regular antenatal check-ups and the pregnancy progressed without any complications. She was admitted at 40 weeks for safe conception. She delivered a female child of weight 3 kgs vaginally. Intrapartum and Postpartum periods were uneventful. The new born did not have any hymenal abnormality. Mother and new born were discharged on postnatal day 2.

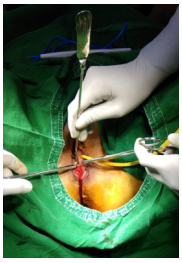

Figure1: Uterine sound can be passed through the pinhole opening.

Figure 2: Hymenectomy after catheterisation of bladder.

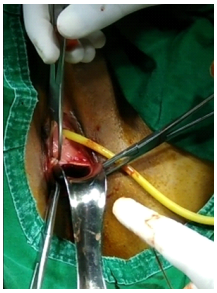

Figure 3: Sims speculum passed after incision to assess introitus.

Figure 4: Mucocutaneous junction sutured with 3-0 vicryl.

DISCUSSION

Female congenital anomalies are uncommon but their impact on reproduction can be profound. During embryonic development, the fused paramesonephric ducts enlarge to form the solid vaginal

cord which later fully canalizes to form the vagina by the 28th week of development. At the junction of the vaginal cord with the urogenital sinus, the hymen remains as a partial septum. The paramesonephric ducts, the mesonephric ducts and urogenital sinus all contribute to the formation of the hymen.[3] Imperforate hymen occurs when the sinovaginal bulb fails to canalize with the rest of the vagina. There is primary amenorrhea but secondary sexual characteristics are well developed. The vaginal outflow is obstructed by the non-perforated hymen and accumulation of menstrual blood leads to mechanical complications such as urinary retention, obstipation or oedema of the legs. Late discovery of an imperforate hymen may lead to pain, infections, hydronephrosis and endometriosis with subfertility.[4] Micro-perforate hymen may present as vaginismus, difficulty in intercourse, infertility but permits passage of menstrual blood. The pinhole opening may allow passage of sperms also, therefore there have been rare case reports of pregnancy. Imperforate hymen should be differentiated from a low transverse vaginal septum using the Valsalva manoeuvre: an imperforate hymen should bulge and a transverse vaginal septum should not.[5] Imperforate hymen is usually not associated with any other Müllerian abnormalities. Transabdominal and transrectal ultrasounds can assist in confirming the diagnosis and ruling out associated anomalies. Minor surgery can fix an imperforate hymen in puberty. There is a virginity sparing (pinhole) surgery but this can still lead to infertility.[6] The complications of surgery are bleeding, scarring and stenosis of the vaginal opening. Less invasive treatments for an imperforate hymen include the use of CO_2 laser.

CONCLUSION

Female genital tract anomalies have an important impact on the sexual activity and fertility. Knowledge about this entity is required to make correct diagnosis and early detection. The history and physical examination are frequently incomplete. One should always consider an imperforate hymen when there is a discrepancy between the Tanner stage and menarcheal status in an adolescent girl with primary amenorrhea and cyclical abdominal pain. Early diagnosis and correct surgical intervention are required for a better psychological and reproductive health.

REFERENCES

1. Guven D, Bakay K, Kuruoglu. Microperforate hymen and infertility: a rare case report. Open J Obstet Gynecol. 2012;2:287-8.
2. Edmonds DK. Congenital malformations of the genital tract. ObstetGynecol Clin North Am. 2000 Mar;27(1):49-62.
3. Gray, S.W, Skandalakis, J.E, and Broecker, B. The female reproductive tract. in: J.E Skandalakis, S.W Gray (Eds.) Embryology for surgeons. 2nd ed. Williams and Wilkins, Baltimore; 1994: 816–847
4. Lardenoije C, Aardenburg R, Mertens H. Imperforate hymen: a cause of abdominal pain in female adolescents. BMJ Case Reports. 2009;2009:bcr08.2008.0722. doi:10.1136/bcr.08.2008.0722.
5. Dane C, Dane B, Erginbas M, et al. Imperforate hymen - a rare cause of abdominal pain: two cases and review of the literature. J PediatrAdolescGynecol 2007; 20: 245-7
6. Temizkan O. Virginity sparing surgery for imperforate hymen: report of two cases and review of literature. J Turkish-German Gynecol Assoc. 2012;13(4):278–80.