



ORIGINAL RESEARCH PAPER

Psychiatry

AMYGDALECTOMY AND SCHIZOPHRENIA: A CASE PERSPECTIVE

KEY WORDS:

Amygdalectomy, Psychosurgery, Schizophrenia

Sail D.B.

Resident, Dept. Of Psychiatry, B.J. G.M.C & SGH, Pune.

Thorat N.M.*

Associate professor, Dept. Of Psychiatry, B.J. G.M.C & SGH, Pune.
*Corresponding Author

Phutane P.V.

Resident, Dept. Of Psychiatry, B.J. G.M.C & SGH, Pune.

ABSTRACT

Introduction: In the past century patients with mental illnesses were treated by invasive brain surgeries which clinically resulted in a variable degree of effectiveness. We report a case of stereotactic amygdalectomy performed in a case of schizophrenia which later required medical management due to failure of the surgical procedure.

Case: A 24 years old unmarried male with a past history of psychiatric illness was brought and admitted for behavioural disturbances. He recently had undergone bilateral amygdalectomy for his illness. A detailed history and mental status examination revealed diagnosis of schizophrenia. He was treated with ECTs and Clozapine on which he showed marked improvement without any side effects.

Conclusion: In patients of schizophrenia psychosurgery shall be an option only after an adequate trial of pharmacotherapy and other treatment modalities.

INTRODUCTION:

World Health Organization defines psychosurgery as "a selective surgical removal or destruction of nerve pathways for the purposes of influencing behavior."^[1] Egas Moniz, a Nobel laureate, gave birth to this field by introducing the idea of operating on the brain for severe anxiety, depression, psychosis, and other psychiatric indications.^[1] The first case of temporal lobe removal was done by Friedrich Golz^[2] after which some taming effect was observed in animals in 1890. Later on, Klüver and Bucy, Thomson and Walker and Schreiner and Kling also demonstrated taming effect of temporal lobectomy and amygdalectomy while working on monkeys and cats.^[2] Terzian and Orecould reproduce these findings after temporal cortical structure and amygdala removal.^[1] Based on these observations a clinical series of 60 patients undergoing stereotactic amygdalectomy for severe aggressive behaviour was reported by Narabayashi et al.^[3] In past century patients with psychiatric disorders were treated using stereotactic lesions and has showed a great range in the effectiveness. Due to advances in pharmacology, skepticism as well as practical banning of psychosurgery there is a significant decrease in the number of the amygdalectomy performed around the world. We report a case of stereotactic amygdalectomy performed in case of Schizophrenia in view of aggression but further treated successfully by medical management due to failure of the surgical procedure.

Case History:

A 24 years old unmarried male resident of rural area of Maharashtra was brought by his father to psychiatric emergency services in view of behavioural problems in the form of muttering and gesturing to self, aggressive, abusive and violent behaviour, irritability, suspiciousness and fearfulness since last 2 weeks. On detailed evaluation he was found to have had similar behaviour disturbances off and on since the last 6 years and was treated by a private psychiatrist in the past with various antipsychotics as well as two separate courses of 8 ECTs (electroconvulsive therapy). However in view of his poor compliance to treatment and persistent symptoms of aggression, irritability and violent behaviour, the patient was taken by his father to a neurosurgeon who advised the patient to undergo neurosurgery as treatment for his illness. Subsequently the patient was operated and bilateral amygdalectomy was performed. His postoperative MRI Brain imaging (Image 1) was suggestive of linear T2W / FLAIR hyperintense tracts noted in the frontal lobe extending to amygdala through corpus striatum bilaterally. These findings were consistent with a postoperative sequel of amygdalectomy. However following the surgery minimum

improvement was perceived by relatives and behavioural disturbances persisted as before. His aggressive and assaultive behaviour increased further hence he was brought to the general hospital and admitted in emergency hours. His physical examination was within normal limits. On the day of admission his mental status examination revealed increased psychomotor activity and reduced reaction time. He had hostile attitude towards clinician. His speech was spontaneous, irrelevant & coherent with increased rate, tone and volume. His affect was irritable. He was reporting delusions of persecution and reference. He was oriented to time, place and person. His immediate, recent and remote memories were intact. His concepts & judgement were impaired. He was lacking insight into his illness.

He was diagnosed to be suffering from Schizophrenia as per DSM 5 criteria. On objective assessment by applying PANSS scale his score was Positive symptoms score 26, Negative symptoms score 15, General Psychopathology Scale score 30 with total score was 71.

His baseline Lab investigations namely CBC, LFT, RFT, CXR, ECG, Sugar & Lipid profile were within normal limits. In view of previous poor response with adequate trial of antipsychotics like Olanzapine, Haloperidol and Risperidone he was started on T. Clozapine 12.5 mg which was gradually uptitrated over next 2 weeks upto 100 mg per day along with monitoring for CBC. He was also posted for modified electroconvulsive therapy in view of severity of symptoms after obtaining fitness from anaesthesia department. Baseline MMSE was done with a score of 30/30. He was given a course of 8 ECTs in total. He showed marked improvement in his behaviour and psychopathology at the completion of a course of ECTs. His PANSS scores were Positive symptoms score 8, Negative symptoms score 9, General Psychopathology Scale score 21 with total score of 38. His MMSE at the time of discharge was 28/30. He was discharged from the ward after 29 days of stay. He was on Tab. Clozapine 200 mg at the time of discharge. Patient was maintaining well on tablet clozapine for almost the next 8 months and still maintaining improvement devoid of any side effects in particular. He is monitored with regular CBC, blood sugar and lipid profile & the above parameters are within normal limits on follow up.

DISCUSSION:

The amygdala plays a regulatory role in anger, aggression and fear.^[2] Animal studies have shown emergence of aggressive reactions after electrical stimulation of the corticomedial region of the amygdala, while significantly

diminished aggression and reduced fear response to threatening stimuli following lesioning of the same anatomical area.^[2] It has also been postulated that there is important role of amygdala in associating stressful stimuli with an autonomic arousal response.^[1] Although the relationship between aggression and autonomic arousal is a complex one, evidence suggests that autonomic arousal is on a continuum with fight-or-flight response.^[1]

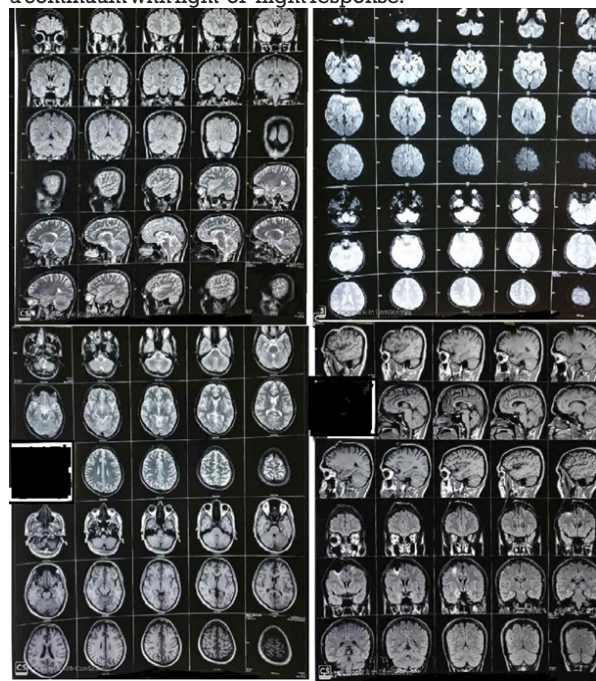


Image 1: Postoperative MRI Brain Imaging Showing Linear T2W / FLAIR Hyperintense Tracts In The Frontal Lobe Extending To Amygdala Through Corpus Striatum Bilaterally.

Numerous series have been published describing outcomes of the amygdalotomy for the treatment of severe aggressive behavior. Narabayashi et al^[3] reported that 85% of patients showed improvement in hyperexcitability, assaultive behavior or violent aggressiveness after undergoing bilateral stereotactic amygdalotomy. Balasubramaniam and Ramamurthireported outcomes of 100 patients who underwent bilateral stereotactic amygdalotomy for assaultive and destructive behavior.^[4] Among this 6% of those had marked behavior improvement with no episodes of violence & did not require any medications, 33% had significant improvement with occasional violent outbursts. 36% of their patients reported some improvement in their symptoms.^[4] Small et aloperated 12 out of 58 patients, for behavior disorders among which approximately one third of their patients experienced behavioral improvement.^[5] Similarly, in the series of 70 patients reported by Mempel et al clinical improvement was observed in 60–70% patients.^[6] Hitchcock and Cairns reported decrease in abnormal aggressive behaviour as well as improvement in maladaptive behaviour after bilateral stereotactic amygdalotomy.^[7] Different complications such as transient ptosis, transient hemiplegia (which was attributed to the close proximity of the crus to the placed lesion) and prolonged postoperative unconsciousness, irregular temperature and convulsions in a patient with postencephalitic aggressive behavioral disturbance were reported in a series reported by Balasubramaniam et al.^[8] Chitanondh and Laksanavicharn in their series reported postoperative loss of libido, increased libido, confusion, hemiparesis and aphasia with complication rate of approximately 32%.^[9] Narabayashi et alin their expanded series reported partial Klüver-Bucy syndrome a week after surgery, with symptoms consisting of unsteadiness, oral tendency, hypersexuality and relative

hypermetamorphosis.^[10] These symptoms lasted for approximately two months and were finally controlled with high doses of chlorpromazine.^[10] Visual discrimination learning is increasingly impaired after combined amygdala-hippocampal lesions as found in numerous animal electrophysiologic studies on monkeys.^[2] Tactile and visual versions of a memory tasks were severely impaired in monkeys with combined hippocampal-amygdala ablations.^[2] A case of face processing impairment after undergoing partial bilateral amygdalotomy.^[2]

Index patient was suffering from Schizophrenia and related violent behaviour. Bilateral amygdalotomy was carried out under NN guidance with three lesions in the right amygdala & two lesions in the left amygdala of 70 degree celsius for 60 sec given. He did not show any marked improvement in behaviour post surgery. There are not ample references for bilateral amygdalotomy in patients suffering from schizophrenia. Probably this index patient would have benefitted with a more aggressive psychopharmacological approach.

There is abandonment of stereotactic amygdalotomy as a treatment for severe aggression or self mutilation disorders due to advances in neuropharmacology as well as existent skepticism for surgical treatment of psychiatric disorders. Such procedures can be considered only in extreme cases after adequate trial of all other therapeutic options and only when the patient and his family are fully aware of the outcome and the risks of the procedure. The cumulative successful outcome of stereotactic amygdalotomy of aggressive behavior occurred in 33–85% of the cases according to various clinical series.^[3-7]

CONCLUSION:

In patients with severe, medically refractory, self-mutilatory or aggressive behavioural disorder bilateral stereotactic amygdalotomy could be considered as the last treatment option after adequate trial of pharmacotherapy and other treatment modalities. A thorough evaluation by more than one psychiatrist and a specialized neurosurgeon is required for the same. If the patient could benefit from a bilateral stereotactic amygdalotomy, then the patient and his family, or legal representative, should be given detailed information of the nature of the procedure, the possible outcome and the potential. Approval of the bioethical committee of the hospital should be taken. The patient should be observed closely after procedure for complications as well as re- emergence of symptoms and should be treated with adequate pharmacotherapy whenever needed.

Declaration Of Patient Consent:

Patient consent statement was taken for publication of the scientific results / clinical information /image without revealing their identity, name or initials. The patient is aware that though confidentiality would be maintained anonymity cannot be guaranteed.

REFERENCES:

1. Fountas, K. N., & Smith, J. R. (2007). Historical evolution of stereotactic amygdalotomy for the management of severe aggression. *Journal of neurosurgery*, 106(4), 710-713.
2. Fountas, K. N., Smith, J. R., & Lee, G. P. (2007). Bilateral stereotactic amygdalotomy for self-mutilation disorder. *Stereotactic and functional neurosurgery*, 85(2-3), 121-128.
3. Narabayashi, H., Nagao, T., Saito, Y., Yoshida, M., & Nagahata, M. (1963). Stereotaxic amygdalotomy for behavior disorders. *Archives of Neurology*, 9(1), 1-16.
4. Balasubramaniam, V., & Ramamurthi, B. (1970). Stereotaxic amygdalotomy in behavior disorders. *Stereotactic and Functional Neurosurgery*, 32(2-5), 367-373.
5. Wogan, M. (1973). Follow-Up of Living Groups in an Experimental Ghetto Program. *Small Group Behavior*, 4(2), 227-244.
6. Mempel, E., Witkiewicz, B., Stadnicki, R., Luczywek, E., Kucinski, L., Pawlowski, G., & Nowak, J. (1980). The effect of medial amygdalotomy and anterior hippocampotomy on behavior and seizures in epileptic patients. In *Advances in Stereotactic and Functional Neurosurgery* 4 (pp. 161-167). Springer, Vienna.
7. Hitchcock, E., & Cairns, V. (1973). Amygdalotomy. *Postgraduate Medical Journal*, 49(578), 894-904.
8. Balasubramaniam, V., & Ramamurthi, B. (1970). Stereotaxic amygdalotomy in behavior disorders. *Stereotactic and Functional Neurosurgery*, 32(2-5), 367-373.

9. Chitanondh, H., & Laksanavicharn, U. (1970). Stereotaxic cryoamygdalotomy. *Internationalsurgery*, 53(5), 329.
10. Narabayashi, H., & Uno, M. (1966). Long range results of stereotaxic amygdalotomy for behavior disorders. *Stereotactic and Functional Neurosurgery*, 27(1-3), 168-171.