PARIPEX - INDIAN JOURNAL OF RESEARCH | Volume - 10 | Issue - 02 | February - 2021 | PRINT ISSN No. 2250 - 1991 | DOI : 10.36106/paripex

ORIGINAL RESEARCH PAPER

Pathology

FINE NEEDLE ASPIRATION STUDY OF THYROID LESIONS IN A TERITIARY CARE HOSPITAL.

KEY WORDS: FNAC, Thyroid lesions, cytology.

Salma Bhat	Associate professor, Department of Pathology Government Medical College Srinagar Kashmir J&K India 190010
Rabiya Rasheed*	Postgraduate scholar Department of Pathology Government Medical College Srinagar Kashmir J&K India 190010*Corresponding Author
Jawad Iqbal Rather	Resident, Department of Nephrology Sher -i- Kashmir institute of Medical Sciences, Kashmir J &K India 190010
Josepheen shahmiri	Resident, Department, Pathology Government Medical College Srinagar Kashmir J&K India 190010

ABSTRACT

FNAC is a crucial initial diagnostic method used in the investigation of thyroid lesions in patients.The aim of this study was to determine the cytological pattern of thyroid lesions. A total of 290 cases with thyroid lesions were studied retrospectively in Govt medical college, Srinagar, Kashmir. Out of which 260 cases, benign lesions (nodular goiter) constituted about 72.69% of all lesions followed by Follicular neoplasm (14%), Papillary carcinoma (11.53%), and two cases each of Medullary and Anaplastic carcinoma. The sensitivity and specificity of FNA 86.8% and 96.2% for malignancy in our study.

INTRODUCTION

Fine needle aspiration cytology represents the crucial initial diagnostic test used for evaluation of thyroid nodules. It is considered to be the gold standard for evaluation of thyroid lesions and is crucial for preoperative assessment. A retrospective study of 290 cases with thyroid swellings was conducted from January, 2019 to April 2020 in the pathology department of Government Medical College and hospital, Srinagar J&K to determine the cytomorphology of the thyroid lesions and to correlate the cytological and histological diagnosis wherever possible. Histopathological correlation was done in the surgically treated cases. FNAC is a simple, cost effective and minimally invasive with few complications. It has high sensitivity in the diagnosis of thyroid malignancies and also has high diagnostic efficacy in the evaluation of other thyroid disorder.

Thyroid nodules are common and are identified in approximately 5% of patients by palpation and 50% by ultrasound examination.1 Fine needle aspiration cytology (FNAC) represents the crucial initial diagnostic test for evaluation of thyroid nodules. FNAC can be relied upon to distinguish benign from malignant thyroid nodules and therefore has caused a dramatic decrease in thyroid surgeries [2]. Cytological diagnosis of thyroid lesions at our institution is influenced by the Bethesda system for reporting thyroid cytology (TBSRTC) which is being accepted and practiced worldwide [3, 4]. The Bethesda System for Reporting Thyroid Cytopathology is a standardized uniform reporting system for thyroid fine-needle aspiration results comprising of 6 diagnostic categories with individualized risks of malignancy and recommendations for further clinical management [5]. Aspiration Cytology (FNAC) of the thyroid gland is a time tested and an established first-line diagnostic test for the evaluation of diffuse thyroid lesions as well as thyroid nodules with the main purpose of confirming benign lesions and thereby preventing unnecessary surgery [6]. FNAC has good amount of accuracy up to 97% in the preoperative diagnosis of various thyroid lesions as claimed by various authors [7, 8].

MATERIAL AND METHODS

A retrospective study of 290 cases with thyroid swellings was conducted from January, 2019 to April 2020 in the pathology department of Government Medical College and hospital, Srinagar J&K to determine the cytomorphology of the thyroid lesions and to correlate the cytological and histological diagnosis wherever possible. Histopathological correlation was done in the surgically treated cases

RESULTS

Most of the patients in our study were in the age group of 30–50 years. There were 85% female and 15% male patients. Out of a total of 290 cases, the FNA sample was adequate in 260 cases Cytological diagnosis of thyroid lesions at our institution is influenced by the Bethesda system for reporting thyroid cytology.

Table 1: Pre-operative FNAC reports.

FNAC	No. of patients
Nodular goiter	186
Lymphocytic thyroiditis	3
Follicular neoplasm	37
Papillary carcinoma	30
Ana plastic carcinoma	2
Medullary carcinoma	2

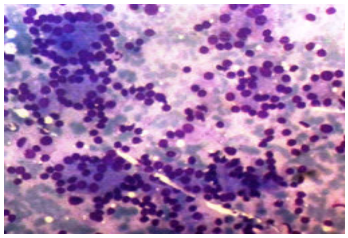

Figure1 Follicular neoplasm showing follicles in a repetitive manner.(40X)

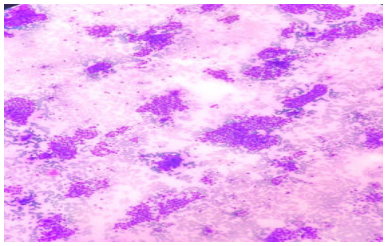

Figure2 PTC showing numerous three dimensional papillary fragments with cells arranged in sheets showing distinct anatomical borders. (40x)

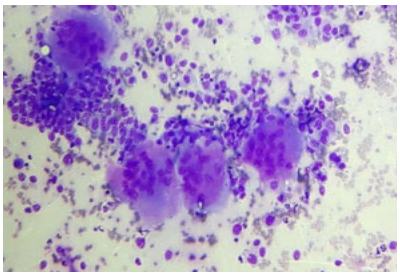

Figure3a cellular smears showing highly pleomorphic cells arranged diffusely in clusters and scattered individually in a hemorrhagic background admixed with multinucleated giant cells.

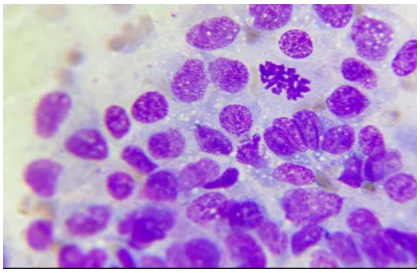

Figure3b.showing cells with prominent nuclear grooving at places and abnormal mitotic figure. (40x)

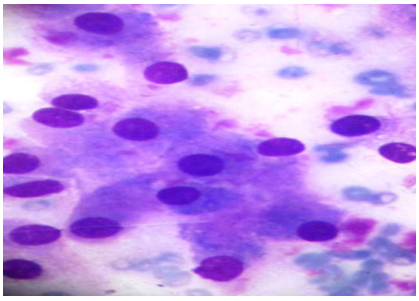

Figure4 .MTC showing predominantly dispersed plasmacytoid cells having abundant amphophilic cytoplasm. Fragments of amyloid also seen. (40x)

DISCUSSION

FNA has been accepted world over as the first-line screening test in the evaluation of thyroid nodules. FNA helps to decide whether a patient requires surgery or whether conservative management will suffice. A diagnosis of neoplasia or malignancy by FNA warrants surgical intervention while benign lesions can be kept under follow up [9].In our study group the age group was in the range of 30-50 years. In a study by B.Nasheen et al, the age group involved by thyroid nodules was 30-40 years [9].

The sensitivity and specificity of thyroid FNACs has been reported as 80%-100% in various studies [9, 10]. In the present study, sensitivity and specificity of FNA for diagnosis of malignancy was 86.8% and 96.2% respectively which was comparable to other studies as well[11].

Follicular neoplasm was the most commonly diagnosed neoplasm in our study (Figure 1). Several studies investigated clinical, ultrasonographic, and cytologic criteria to predict malignancy in follicular lesions. However, the topic of risk factors predicting malignancy in thyroid nodules with a diagnosis of follicular neoplasm is still controversial. In the current study, our findings extend previous reports that noted that older age, male sex, solitary nodule, and larger size of the nodule were not predictive for malignant neoplasms [12, 13]. There were 30 cases of papillary carcinoma in all in our study. The cytological appearance of PTC has been well defined by different authors and were used in our study for the final cytological diagnosis (Figure 2).In a study by Chandanwale et al [14]malignant lesions were 4% out of which 2.6% were papillary carcinoma. In the study done by Moosa et al [15], malignant lesions were 7.9% out of which 6.8% were papillary carcinoma. There were 2 cases each of anaplastic and medullary carcinoma in our study. The smears in anaplastic carcinoma showed neoplastic cells arranged in loose clusters as well as dispersed individually in a hemorrhagic background. The individual cells showed malignant cytologic features including large, pleomorphic nuclei with irregular nuclear membranes, hyperchromasia and prominent nucleoli (Figure 3) (Figure 3b).

Medullary carcinoma constitutes approximately 5% of thyroid carcinomas in other studies which was comparable to our observation [16]. Although the detection rate of MTC by cytology alone is less convincing, correlation with ancillary tests can achieve an excellent diagnostic accuracy. The recognition of constitutive cytomorphological features is needed for each cytopreparatory method, which may result in a lower threshold to initiate further workup for MTC. Microscopic examination of medullary carcinoma showed clusters as well as single dispersed plasmacytoid cells. The cells had eccentric nuclei with coarse chromatin and abundant amphophilic cytoplasm [Figure 4]. Small clumps of amyloid-like amorphous, glassy, eosinophilic material were seen in the background. A diagnosis of the medullary thyroid carcinoma (plasmacytoid type) was made on the basis of these cytological findings.

CONCLUSION

FNAC is a crucial in the management of thyroid lesions with a high degree of accuracy. It is safe, simple, and cost effective with negligible major complications and can be performed on out- patients with good patient compliance. FNAC provides a more rapid and accurate diagnosis of thyroid lesions than any other combination of clinical laboratory tests. But, Histopathology is mandatory particularly in malignant neoplasms to confirm the diagnosis and for further management.

Funding: Nil
Conflict of interest: Nil

References

1. Gharib H, Papini E. Thyroid nodules: clinical importance, assessment, and treatment. Endocrinol Metab Clin North Am. 2007;36:707.
2. M.K. Sidawy, D.M. Del Vecchio, S.M. KnollFine-needle aspiration of thyroid nodules: correlation between cytology and histology and evaluation of discrepant cases .Cancer, 81 (1997), pp. 253-259.
3. Melo-Uribe, M. A., Sanabria, Á., Romero-Rojas, A., Pérez, G., Vargas, E. J., Abaúnza, M. C., & Gutiérrez, V. (2015). The Bethesda system for reporting thyroid cytopathology in Colombia: Correlation with histopathological diagnoses in oncology and non-oncology institutions. Journal of cytology, 32(1), 12–16.
4. C. Ravetto, L. Colombo, M.E. Dottorini. Usefulness of fine-needle aspiration in the diagnosis of thyroid carcinoma: a retrospective study in 37,895 patients.Cancer, 90 (2000), pp. 357-363.
5. Wong LQ, Baloch ZW. Analysis of the bethesda system for reporting thyroid cytopathology and similar precursor thyroid cytopathology reporting schemes. Adv Anat Pathol. 2012;19(5):313-319.
6. Rathod GB., Rai P., Rai S. 2015. A prospective study of ultrasonographic and FNAC correlation of thyroid pathology. IAIM, 2(11): 46-51.
7. Yoon JH., Kwak JY., Moon HJ., Kim MJ., Kim EK. 2011. The diagnostic accuracy of ultrasound- guided fine-needle aspiration biopsy and the sonographic differences between benign and malignant thyroid nodules 3□ cm or larger. Thyroid, 21(9):993-1000.
8. Gunvanti Rathod, Pragnesh Parmar. 2012. Fine needle aspiration cytology of swellings of head and neck region. Indian Journal of Medical Sciences, 66: 49-54.
9. Nasheen Bagali, Maheboob Bagali and Praveen Kumar, S.P 2019. "Role of FNAC in Goiter", International journal of Current Research, 11,(11),8131-8133.
10. Baloch ZW, LiVolsi VA, Asa SL, et al. Diagnostic terminology and morphologic criteria for cytologic diagnosis of thyroid lesions: a synopsis of the National Cancer Institute Thyroid Fine-Needle Aspiration State of the Science Conference. Diagn Cytopathol. 2008;36:425–37.–35.
11. Ajay K B, Sreejayan MP, Vaisagh R. Accuracy of Fnac in Diagnosing Thyroid Nodules: A Single Institution Experience. Biomed J Sci&Tech Res 1(4)- 2017.
12. Sahin MGursoy ATutuncu NBGuvener DN Prevalence and prediction of malignancy in cytologically indeterminate thyroid nodules. Clin Endocrinol

(Oxf) 2006;65 (4) 514- 518.
13. Miller BBurkey SLindberg GSnyder WHNwariaku FE Prevalence of malignancy within cytologically indeterminate thyroid nodules. Am J Surg 2004;188 (5) 459- 462.
14. Chandanwale S, Singh N, Kumar H, Pradhan P, Gore C, Rajpal M. Clinicopathological correlation of thyroid nodules.Int J Pharm Biomed Sci 2012;3(3):97-102.
15. Foad Ali Moosa et al: Upto what extent FNAC is accurate in detecting malignancy in solitary thyroid nodule? (A comparison with post-operative histopathology findings). Medical Channel 2010;16(2).
16. Agarwal C, Raychaudhuri S, Batra A, Pujani M, Dhingra S. Medullary carcinoma of thyroid mimicking Hurthle cell neoplasm on cytology: a diagnostic dilemma. Diagn Cytopathol. 2019;47(9):943-947.