



ORIGINAL RESEARCH PAPER

General Surgery

INTRAMUSCULAR HEMANGIOMA OF THE MASSETER MUSCLE:A CASE REPORT

KEY WORDS: Intramuscular hemangioma, Vascular tumour, Masseter muscle

Dr.K.Anandan

Assistant Professor, Institute of General Surgery, Madras Medical College and Rajiv Gandhi Government General Hospital, Chennai.

Dr.S.Swetha Priyadharshini*

Postgraduate, Institute of General Surgery, Madras Medical College and Rajiv Gandhi Government General Hospital, Chennai. *Corresponding Author

Prof.Dr.R. Kannan

Director, Institute of General Surgery, Madras Medical College and Rajiv Gandhi Government General Hospital, Chennai.

ABSTRACT

Background - Intramuscular hemangiomas are benign vascular tumours that most frequently occur in the trunk and extremities. They constitute about <1% of all hemangiomas, only 10%–20% have been found to arise in the head and neck region, and 36% of cases involving masseter muscle. They usually present as gradually enlarging soft-tissue mass with or without pain. They are located deep within the muscle, hence rarely exhibit clinical signs or symptoms such as bruits, thrills, pulsation which are suggestive of vascular origin. Due to their rare occurrence, unique location they are often confused with other soft-tissue pathologies such as parotid swelling or other muscular lesions.

Case report - 21 year old male came with complaints of swelling and pain over the left cheek for past 6 months which was insidious in onset and non progressive. Patient did not have any history of trauma or increased salivation. On examination swelling of about 2*2 cm over the left cheek, well defined, non tender, soft in consistency. There was no pulsation, bruits or palpable thrill. There was no compressibility and the overlying skin was normal. There was no facial nerve involvement and parotid duct orifice was normal.

Conclusion - The possibility of an Intramuscular hemangioma of the masseter muscle should be included in the differential diagnosis of any intra-masseteric lesion. Appropriate radiologic examinations, especially MRI, can enhance accurate preoperative diagnosis; the treatment of choice should be individualized in view of the clinical status of the patient.

INTRODUCTION -

Intramuscular hemangioma (IMH) is a rare vascular disease involving skeletal muscle, comprising only 0.8% of all hemangiomas. About 10% to 20% of Intramuscular hemangiomas may occur in the head and neck region, involving the masseter muscle. Intramuscular hemangioma of the head and neck may be localized mainly in the masseter muscle (36%), trapezius (24%), periorbital muscles (12%), sternocleidomastoid muscle (10%), temporalis muscle, or orbicularis oris muscle.

Intramuscular hemangioma occurs mostly in childhood. However, it often is not found until unexpected enlargement, pain, or cosmetic asymmetry occurs in adulthood. Several non-surgical treatments including cryotherapy, sclerosant injection, and arterial ligation have been described, but complete surgical resection is the curative intervention. In the case of a large feeding vessel, embolization of the feeding vessels is recommended to reduce the risk of perioperative and postoperative bleeding.

Case report -

21 years old male came with chief complaints of swelling and pain over the left cheek for 6 months duration. The swelling was insidious in onset, non progressive, constant in size, not associated with food intake, associated with pain which was pricking type and the pain not referred to left ear. Patient did not have any history of increased salivation or difficulty in opening and closing the mouth. Patient did not have any previous history of trauma to the left cheek.

On examination, General condition and vital signs of the patient was stable. Local examination of left cheek had swelling of about 2*2 cm around the region of parotid, about 3 cms in front of tragus, well defined swelling, which was not tender, soft in consistency, bidigitally palpable. The swelling decreased on opening the mouth and becomes more prominent on clenching the teeth. There was no pulsation, bruits or palpable thrill. There was no compressibility and the overlying skin was normal. There was

no facial nerve involvement and parotid duct orifice was normal. Oral cavity examination was normal and there was no palpable cervical nodes.



Figure 1: Clinical image of the patient showing swelling over the left cheek

Complete hemogram done which was normal. Other laboratory parameters, liver and kidney function test, serum electrolytes were normal. No abnormalities in echocardiogram and chest X-ray.

High frequency USG of left cheek revealed soft tissue lesion of 12*10mm anterior to the left parotid gland with internal vascularity and mild perilesional inflammation, probably a vascular malformation. MRI revealed well defined T1 and T2 hyperintense lesion measuring 18mm (antero posterior), 13mm (mediolateral) and 20mm (craniocaudal) visualised within left masseter muscle. Draining veins seen around the lesion suggestive of hemangioma. No evidence of adjacent soft tissue component or bony erosion.

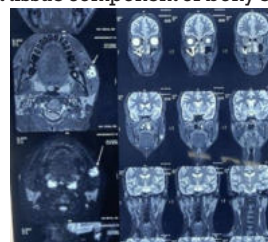


Figure 2: MRI image depicting hemangioma

Proceeded with excision. Skin incision made over the swelling and tumour of size 2*2 is found beneath the masseter muscle. Masseter split opened, feeding vessels were lighted and hemangioma excised in toto.

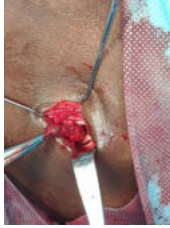

Figure 3: Intraoperative image showing intramuscular hemangioma excised by splitting up the masseter muscle

Postoperatively patient was stable and did not show any signs of parotid duct obstruction or facial nerve palsy.

Histopathology revealed fibrocollagenous and fibromuscular tissue with numerous dilated vascular spaces filled with organised thrombi. Stroma shows lymphocytes, histiocytes, areas of hemorrhage and pigment laden macrophages. Focal calcifications seen suggestive of intramuscular hemangioma.

DISCUSSION -

Intramuscular hemangiomas are most commonly seen among adolescents and young adults, especially before the age of 30(1,2); however, they may affect older patients. Although Intramuscular hemangioma have shown an equal sex distribution, involvement of the masseter has a definite male predominance(3). It has been suggested that they arise from malformed tissue that has been subjected to repeated trauma or as the result of hormonal factors(4). Intramuscular hemangiomas progressively enlarge but never metastasize(5).

Intramuscular hemangiomas generally present as progressively enlarging and often painful lesions. Because of their deep location, they rarely display any clinical signs or symptoms that suggest a vascular nature, such as pulsations, thrills, or bruits. Overlying skin discoloration is also uncommon. The absence of pathognomonic clinical findings and the rare incidence of these lesions make accurate pre-operative diagnosis difficult(6,7).

Intramuscular hemangiomas appear to grow as non-encapsulated masses characterized by a multicentric proliferation of cords of endothelial cells that subsequently canalize. The characteristic of locally invasive tumor involved growth along planes of least resistance. It is confined to a single muscle in 80% of cases.

Histologically, the lesions are classified as capillary (vessels smaller than 140 micrometers in diameter), cavernous (vessels larger than 140 micrometers in diameter), or mixed(8). Capillary hemangioma is the most frequent hemangioma, located in the cutaneous or subcutaneous tissues and diagnosed in the first decade of life. Most instances of capillary hemangioma undergo involution spontaneously. Cavernous hemangiomas are large and deeply located and are diagnosed later in life; these lesions are frequently intramuscular, do not have spontaneous involution, and require surgical treatment. Mixed hemangioma is, microscopically, a mixture of capillary and cavernous hemangioma(9).

Ultrasound examinations, shows a heterogeneous, echogenic, cystic mass with posterior acoustic shadowing secondary to the calcified nodular areas. With non-enhanced CT, an ill-defined mass of similar attenuation to muscle may be identified. After administration of contrast material, significant enhancement is seen. Currently, MRI is the standard imaging technique for diagnosing soft-tissue

hemangioma. On T1-weighted images, compared with muscle tissue, intensities of the lesions are isointense or hyperintense with unclear margins. On T2-weighted images, hemangiomas are typically hyperintense and have clear margins and lobulated contours(10,11).

Marked hyperintensity of the lesions on T2-weighted images is due to increased fluid content secondary to stagnant blood flow in large vessels. Hemorrhagic and calcified areas and fatty tissue located in the hemangioma are responsible of heterogeneous signal intensity on T1- and T2-weighted sequences. Punctuate or reticular low signal intensity areas represent fibrous tissue, fast flow within the vessel, or foci of calcifications. Angiography delineate the vascular nature of an intramuscular hemangioma and the feeding artery.

Management of intramuscular hemangiomas should be individualized according to the size and anatomic accessibility of the tumor, its growth rate, age of the patient, and cosmetic and functional considerations(12). Many forms of therapy have been suggested, including steroid injections, radiation therapy, injection of sclerosing agents, cryotherapy, and electrocoagulation. However, the optimal management is surgical resection. Local recurrence rates ranging from 9% to 28% have been reported.

CONCLUSION -

Intramuscular hemangiomas should be considered in the differential diagnosis, whenever a soft tissue lesion in a skeletal muscle of a young adult is encountered. Sonography and MRI are excellent diagnostic aids in such lesions. Management options should be individualised in view of clinical status of the patient.

Conflict of interests -

The authors declare that they have no conflict of interest regarding the publication of this paper

Funding - None

Ethical approval -

Not required

REFERENCES -

1. Fletcher CD, Unni KK, Mertens F, editors. Pathology and genetics of tumors of soft tissue and bone. Lyon: IARC Press; 2002. World health organization: Classification of tumors.
2. Weiss SW, Goldblum JR. Benign tumors and tumor-like lesions of blood vessels. In: Weiss SW, Goldblum JR, editors. Enzinger and Weiss's soft tissue tumors. 4th ed. St. Louis: C.V. Mosby; 2001. pp. 837-90.
3. Hoehn JG, Farrow GM, Devine KD. Invasive Hemangioma of the Head and neck. Am J Surg. 1970;120:495-98.
4. Zengin AZ, Celenk P, Sumer AP. Intramuscular hemangioma presenting with multiple phleboliths: a case report. Oral Surg Oral Med Oral Pathol Oral Radiol. 2013;115(1):e32-36.
5. Jones KG. Cavernous haemangioma of striated muscle - a review of literature and a report of four cases. J Bone Joint Surg Am. 1953;35-A(3):717-28.
6. Avci G, Yim S, Misirligolu A, et al. Intramasseteric hemangioma. Plast Reconstr Surg. 2002;109:1748-49.
7. Demir Z, Oktem F, Celebioglu S. Rare case of intramasseteric cavernous hemangioma in a three-year-old boy: a diagnostic dilemma. Ann Otol Rhinol Laryngol. 2004;113:455-58.
8. Wolf GT, Daniel F, Arbor A, Krause CJ. Intramuscular haemangioma of the head and neck. Laryngoscope. 1985;95:210-13.
9. Olsen KI, Stacy GS, Montag A. Soft-tissue cavernous hemangioma. Radiographics. 2004;24:849-54.
10. Vilanova JC, Smirniotopoulos JG, Perez-Andres R, et al. Hemangioma from head to toe: MR imaging with pathologic correlation. Radiographics. 2004;24:367-85.
11. Bayarogullari H, Gokkeser Y, Akbay E, et al. Intramuscular cavernous hemangioma. J Clin Exp Invest. 2012;3(3):404.
12. Terezhalmay GT, Riley CK, Moore WS. Intramuscular hemangiomas. Quintessence Int. 2000;31(2):142-43.