



ORIGINAL RESEARCH PAPER

Orthopaedics

**CASE REPORT OF A RARE DISEASE :
MELORHEOSTOSIS**

KEY WORDS:

Melorheostosis; Leri disease;
Osteopathica striata.

Anvith Shetty

Resident, Department of Orthopaedics, JJM Medical College, Davanagere, Karnataka, India

ABSTRACT

Introduction: Melorheostosis is a rare, non-genetic, non-developmental, sclerosing developmental dysplasia of bone and adjacent soft tissue. The characteristic radiographic appearance is that of candle wax dripping. Diagnosis is usually based on classical radiographic appearance rather than clinical picture. **Case report:** A 26 year old female with dull aching pain over upper third left leg and knee with limitation in movements and associated swelling. On examination tenderness and limitation of movements were present. Plain radiograph showed extensive, dense, undulating or irregular cortical hyperostosis, resembling candle wax dripping along length of left tibia suggestive of Melorheostosis and MRI showed features of Osteopathica striata of left femur and Osteopoikilosis of left hip joint. Inj. Zolindronic acid given. Physiotherapy was started to avoid contractures. **Conclusion:** Lab investigations in Melorheostosis is usually normal. Exact pathophysiology of the disease remains uncertain. No curative treatment options are available. Bisphosphonates, Denosumab and physiotherapy are the available options for treatment.

INTRODUCTION

Melorheostosis is a rare, nonhereditary sclerosing bone dysplasia first described in 1922 by Leri and Joanny [1]. The minimal prevalence has been estimated to be 0.9 per million [2]. It got this name because of the characteristic periosteal hyperostosis along the cortex of long bones which looks similar to the flowing or dripping of candle wax (originated from Greek, melos = limb, rhein = to flow, ostos = bone) [3-5]. Melorheostosis is also known by other synonyms such as candle disease of the bone, and osteosis eburnisans monomelica [6,7]. This condition may affect only one bone (monostotic form), one limb (monomelic form), or multiple bones (polyostotic form). Establishing the diagnosis in melorheostosis is challenging. It is primarily based on radiological findings as defined by Freyschmidt [8] and on the exclusion of other sclerosing bone diseases. It is a chronic progressive disorder and affects females and males equally [8]

CASE REPORT

A 26 year old female came with complaints of dull aching pain over the left upper third leg and knee, which was insidious in onset, which has gradually increased and associated with swelling over the left leg since past 2 years and came to our OPD. She has consulted with orthopedicians from multiple hospitals, where radiographs were taken and further MRI had been suggested. Patient was given analgesics and was advised physiotherapy and she does not give any relevant history of trauma to the affected limb in the recent past or before the pain started 2 years ago.

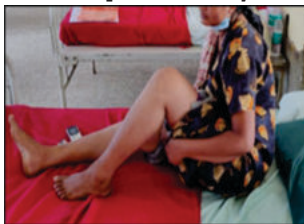

Fig.1.1

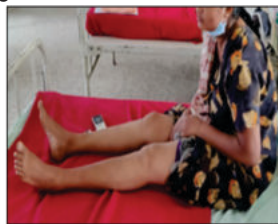

Fig.1.2

On physical examination swelling was tender on palpation and bony hard in consistency with irregular surface.

Further, there was limited flexion of around 100 degrees at the left knee joint with no limitation in extension (fig.1.1 and fig. 1.2) which was associated with pain.

Plain radiograph of the left femur and tibia (fig. 1.3 and fig. 1.4) revealed an extensive, dense, undulating or irregular cortical hyperostosis, resembling candle wax dripping, extending along the length of bone, resulting in deformity of the bone and narrowing of the medullary cavities.

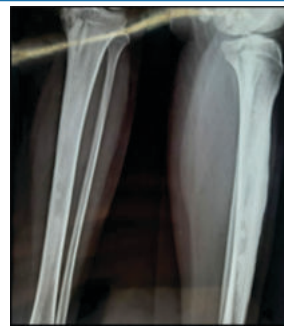

Fig.1.3

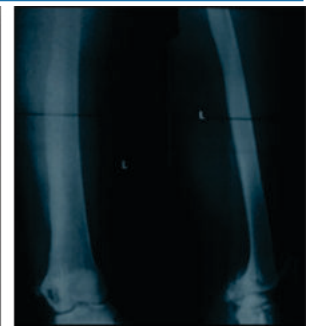

Fig.1.4

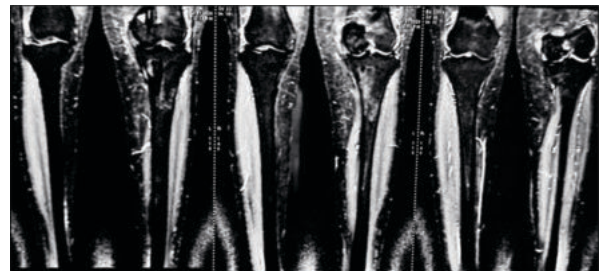


Fig.1.5

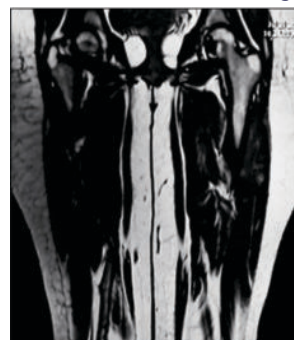


Fig.1.6

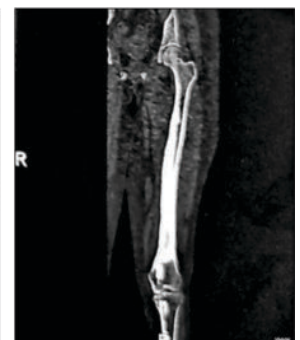

Fig.1.7

Laboratory investigations such as CBC, ESR, CRP, Serum Calcium, Serum phosphorous, Alkaline phosphatase were within normal limits

Further MRI of left lower limb showed flowing irregular cortical thickening of 2cm thickness along medial aspect of entire femur and along medial and anterior aspect of entire tibia (sparing distal tibial epiphysis) with thick undulating ridges of bone giving a flowing candle wax appearance (fig. 1.5) suggestive of Melorheostosis.

Few linear vertical dense striations seen oriented parallel to long axis of femur predominantly involving lower metaphysis giving a celery stalk metaphysis appearance suggestive of Osteopathica Striata (fig.1.7)

Multiple enostoses/ bone islands clustered around the hip joint seen suggestive of Osteopoikilosis (fig 1.6)

Treatment included daily analgesics and bisphosphonates-Zolindronic acid 5mg, and daily physiotherapy to avoid soft tissue contractures.

Patient reported alleviation of pain and advised to continue physiotherapy to avoid development of any deformities.

DISCUSSION

Melorheostosis is a rare mesenchymal disease affecting the skeleton and adjacent soft tissue. It is a type of sclerosing bone dysplasia. [9]

Exact etiology of the disease is unknown but literature suggests that loss of function mutation of cell adhesion molecules coded by LEMD3 gene, a protein involved in bone morphogenic protein and tumor growth factor- β signaling may be the cause in melorheostosis and other diseases like Osteopoikilosis and Buschke Olendorff syndrome. [10]

Another possible etiology is altered expression of several adhesion proteins may contribute to the development of hyperostosis and concomitant soft tissue abnormalities of melorheostosis, with Beta-IGH3 in particular playing an important role in osteogenesis. [11]

Male and female are equally affected, and no hereditary features have been discovered. The onset of this rare diseases is insidious, and the first symptom is usually pain because of the sub periosteal bone formation. Range of movement limitation and joint deformities develop gradually. Limb length discrepancy and joint contractures may be seen in Melorheostosis. Soft tissue involvement in the form of soft tissue masses, scleroderma and vascular malformations are also reported [12,13,14]

Radiologic patterns on plain radiographs of Melorheostosis include [5]

- Osteoma like pattern
- Classical candle wax like pattern
- Osteopathica striata pattern
- Myositis ossificans pattern
- Mixed pattern

In most cases, biopsy is not needed for the diagnosis of Melorheostosis, but it may be useful in case of uncertain radiographic appearance and dignity of a lesion. Most biopsy sections present a nonspecific image with dense cortical thickening with islands of cartilage, surrounded by lamellar bone in normal or irregular Haversian systems. Morris described (1963) in his sections dense bone mass with irregular pattern of the Haversian systems, vascular obliterations and inflammatory cells within surrounding mesenchymal tissue with areas of metaplastic cartilage. Enlarged and thickened bony trabeculae, that contain normal-appearing haversian systems, which may be irregularly arranged or almost obliterated, are characteristic histologic appearances in most cases of Melorheostosis [12]. Intraarticular melorheostosis can present the characteristics mentioned above together with cartilaginous formations or a capping of hyaline cartilage, what may lead to misdiagnosis of a highly differentiated chondrosarcoma or osteochondroma.

Treatment options for Melorheostosis is limited and none of them have yielded successful cure from disease.

Nonoperative therapeutic options in symptomatic

melorheostosis include physical and ergotherapy, nonsteroidal and opioid analgesics. There are also isolated case reports of successful management of pain with bisphosphonates in literature. Denosumab has a place in the treatment of melorheostosis when the effect of bisphosphonate treatment is insufficient [15]

Surgical options include resection of the osteosclerotic masses from osseous and soft tissues, decompression of nerves and vessels, capsulotomy, tendon release and fasciotomy for pain and contracture management, often with uncertain results.

Amputations are rare. Due to the high recurrence rates of contractures, surgical procedures should be performed at the end of growth or a combination of surgical procedure and brace therapy or external fixation should be forced in phases of growth acceleration. Shortening of the contralateral limb is the preferred option in the management of limb length inequality.

CONCLUSION

Melorheostosis is very rare benign disease. It is diagnosed by characteristic x-ray finding. There is no definite treatment available only symptomatic treatment is given. However, newer modalities of treatment such as Denosumab, Bisphosphonates have shown improvement in symptoms. However more research need to be done in this direction.

REFERENCES

1. Leri A, Joanny J. Une affection non décrite des os hyperostose "en coulée" sur toute la longueur d'un membre ou "melorhéostose". Bull Mem Soc Med Hosp Paris. 1922;46:1141-5.
2. Wynne-Davies R, Gormley J. The prevalence of skeletal dysplasias. An estimate of their minimum frequency and the number of patients requiring orthopedic care. J Bone Jt Surg Br. 1985;67-B(1):133-7.
3. Campbell CJ, Papadetriou T, Bonfiglio M. Melorheostosis. A report of the clinical, roentgenographic, and pathological findings in fourteen cases. J Bone Joint Surg Am. 1968;50:1281-1304.
4. Taylor PM. Melorheostosis. J Foot Surg. 1976; 15:55-58.
5. Freyschmidt J. Melorheostosis: A review of 23 cases. Eur Radiol. 2001; 11:474-479.
6. Ihde LL, Forrester DM, Gottsegen CJ, Masih S, Patel DB, Vachon LA, White EA, Matcuk GR Jr. Sclerosing bone dysplasias: Review and differentiation from other causes of osteosclerosis. Radiographics. 2011;31:1865-1882.
7. Rozencaiga R, Wilson MR, McFarland GB Jr. Melorheostosis. Am J Orthop. 1997;26:83-89.
8. Greenspan A, Azouz EM. Bone dysplasia series. Melorheostosis: Review and update. Can Assoc Radiol J. 1999;50:324-330.
9. Freyschmidt J. Melorheostosis: A review of 23 cases. Eur Radiol. 2001; 11:474-479.
10. Moreno Alvarez MJ, Lázaro MA, Espada G, Barceló HA, Maldonado Cocco A. Linear scleroderma and melorheostosis: Case presentation and literature review. Clin Rheumatol. 1996; 15:389-393.
11. Kim J-E, Kim E-H, Han E-H, et al. ATGF- β -inducible cell adhesion molecule, Big-h3, is downregulated in melorheostosis and involved in osteogenesis. J Cell Biochem 2000;77: 169-78.
12. Morris JM, Samilson RL, Corley CL. Melorheostosis. Review of the literature and report of an interesting case with nineteen year follow up. J Bone Joint Surg 1963;45A:1191-2000.
13. Judkiewicz AM, Murphey MD, Resnik CS, et al. Advanced imaging of melorheostosis with emphasis on MRI. Skeletal Radiol 2001;30:447-53.
14. Ethunandan M, Khosla N, Tilley E, Webb A. Melorheostosis involving the craniofacial skeleton. J Craniofac Surg. 2004;15:1062-1065.
15. Byberg et al. Clinical improvement in a patient with monostotic melorheostosis after treatment with denosumab: a case report. Journal of Medical Case Reports (2018) 12:278