



## ORIGINAL RESEARCH PAPER

Anatomy

### A RARE VARIATION IN THE BRANCHING PATTERN OF FEMORAL ARTERY ON LEFT SIDE

**KEY WORDS:** Trifurcation, Lateral Circumflex Femoral Artery, Angiographies

|                                |   |
|--------------------------------|---|
| <b>Janpreet Singh Kala*</b>    | Department of Anatomy, Armed Forces Medical College, Pune.<br>*Corresponding Author |
| <b>Avi Tyagi</b>               | Department Of Physiology Armed Forces Medical College, Pune.                        |
| <b>Vishen Dev Singh Jamwal</b> | Department of Anatomy, Armed Forces Medical College, Pune.                          |
| <b>B Subhash</b>               | Department Of Anatomy, All India Institute Of Medical Sciences Kalyani.             |
| <b>Debases Bandyopadhyay</b>   | Department of Anatomy, Armed Forces Medical College, Pune.                          |
| <b>Aseem Tandon</b>            | Department of Anatomy, Armed Forces Medical College, Pune.                          |

#### ABSTRACT

**Background:** The Femoral artery is the principle artery of the lower limb. It is the continuation of the external iliac artery and enters the anterior compartment of the lower limb through femoral triangle behind the inguinal ligament at the mid inguinal point. It is commonly accessed for angiographies, insertion of central lines, ultrasound & Doppler imaging, digital subtraction angiography, magnetic resonance imaging and other various investigative and diagnostic procedures. Lateral circumflex femoral artery and its branches are used as grafts in various bypass surgeries in ilio-femoral region as well as in cranial cavity. Precise knowledge of anatomical variations of femoral artery is important for clinicians in the present modern era of interventional radiology. In the present study, a case of trifurcation of branching pattern was seen between femoral artery, profunda femoris artery and lateral circumflex femoral artery. **Methods:** During the routine dissection of 30 cadavers, the case was seen in the left limb of one male cadaver in the Department of Anatomy, Armed Forces Medical College Pune. **Observation:** a trifurcating branching pattern was observed between femoral artery profunda femoris artery and lateral circumflex femoral artery. **Conclusion:** The knowledge of the variation in the branching pattern of femoral artery can provide leading edge in the vascular surgery and its angiographic applications which may reduce the complications during interventional procedures of femoral artery.

#### INTRODUCTION

The femoral artery is a major blood vessel of the lower limb. It is the continuation of the external iliac artery in the lower limb. It starts posteriorly to the inguinal ligament midway between the anterior superior iliac spine and pubic symphysis then continues along the anteromedial part of the thigh in the femoral triangle and enters the adductor canal through the adductor hiatus and becomes the popliteal artery near the junction of middle and distal 3<sup>rd</sup> of the thigh. [1]. Histological is the type muscular artery and tunica intima and tunica media in the ratio of 1:1. [2]. Its gives off various branches including superficial branches and deep branches in the thigh. Among the deep branches the profunda femoris artery is the chief branches of femoral artery. From the profunda femoris artery there are 2 major vessels which arise namely medial circumflex femoral artery from medial aspect and lateral circumflex artery from lateral aspect. The lateral circumflex artery lies on the lateral aspect and is present between the anterior and posterior division of femoral nerve. [3]. Sometimes a variation is seen in which the medial and lateral circumflex arteries arise directly from the femoral artery. In our case a trifurcating branching pattern was observed between profunda femoris artery femoral artery and lateral circumflex femoral artery. The reason for the variation of branching pattern of femoral artery lies in the embryology development of the arteries of the lower extremities. Normally in the foetal life, the sciatic artery, a branch of the internal iliac artery, is initially responsible for the vascularisation of the entire lower limb; however, when the foetus is eight weeks old and 10 mm long, it regresses and this function is taken over by the FA, a branch of the external iliac artery. [4]. Any variation in this process of development will lead to the variation in the branching pattern of femoral artery. This knowledge on the branching pattern of the arteries of lower limb provides a leading edge in various inventional procedures like arterio-venous fistulas, anterolateral thigh flaps and coronary artery bypass grafts.

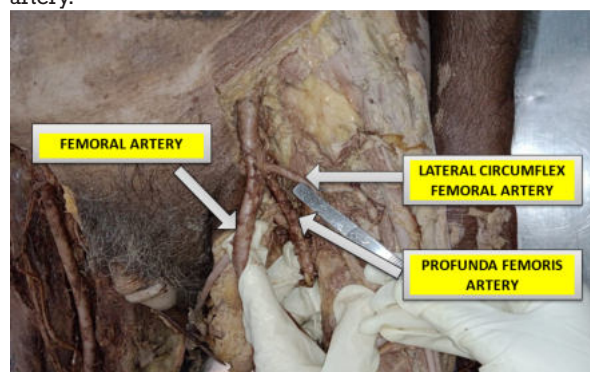
[5]. Lateral circumflex femoral artery and its branches are used in various bypass surgeries in iliofemoral region as well as in cranial cavity. [6].

#### MATERIAL AND METHODS:

During the routine dissection of 30 cadavers in the year 2022, the case was seen in one male cadaver aged between 60-70 years in the Department of Anatomy, Armed Forces Medical College Pune.

#### OBSERVATION:

A trifurcation pattern was seen between femoral artery, lateral circumflex femoral artery and profunda femoris artery. The lateral circumflex artery is originating from femoral artery from the lateral aspect about 2 cm below the mid-inguinal point and above the origin of profunda femoris artery.



**Fig 1** Showing Trifurcation Between Femoral Artery Profunda Femoris Artery And Lateral Circumflex Artery

#### DISCUSSION

The origin of lateral circumflex artery directly from the

femoral artery has been observed in many studies. Some of studies are given in table 1.

**Table 1 Comparison Of Studies Showing Origin Of Lateral Circumflex Femoral Artery**

| Study                    | From femoral artery               | From profunda femoris artery      |
|--------------------------|-----------------------------------|-----------------------------------|
| Fakuda et al 2005 [7]    | 21.4%                             | 78.6%                             |
| Uzel M et al 2008 [8]    | 22.7%                             | 77.3%                             |
| Prakash et al 2010 [9]   | 18.75%                            | 81.25%                            |
| Sinket et al 2012 [10]   | 13.1%                             | 65.55%                            |
| Manjappa et al 2014 [11] | Right side: 20%<br>Left side: 30% | Right side: 80%<br>Left side: 70% |
| Tzouma G et al 2020 [12] | 12.12%                            | 74.92%                            |

According to William et al study, both circumflex arteries were originating from femoral artery in only 56 % of cases. A case report was noted in a study by Savithri et al in which a similar trifurcation was seen between femoral artery, profunda femoris artery and lateral circumflex femoral artery. The trifurcation was located approximately 7 mm below the inguinal ligament. Lateral circumflex femoral artery originated with an external diameter of 5 mm. In addition to that the artery branched in to ascending, transverse, descending and muscular arteries. [13]. According to Choi SW et al the origin of lateral circumflex femoral artery from femoral including common stem is seen in 13.2% of cases [14]

## CONCLUSION

The knowledge of anatomical variations of the branching pattern of femoral artery and its branches is very helpful in this modern era of interventional radiology. The circumflex vessels from femoral artery not only acts as a branching vessels but also as collateral vessels in case of occlusion of the femoral artery to restore the blood supply of lower limb. The application of this knowledge is helpful in avoiding iatrogenic femoral arterio-venous fistula formed during puncture of femoral artery. In addition, the knowledge of origin of lateral circumflex femoral artery can be helpful in surgeries of ilio-femoral region and also can be used in creating antero lateral thigh flaps and in coronary by-pass graft surgeries.

## REFERENCES

- [1] Stranding S. Gray's anatomy The Anatomical basis of clinical practice 41<sup>st</sup> edition Elsevier .2016 p.1337
- [2] Pawlina W. Ross histology textbook and atlas 8<sup>th</sup> edition wolters Kluwer 2020 p.440
- [3] Sinnatambay CS. Last's Anatomy Regional and Applied. 10th Ed., Churchill Livingstone. 1999;114-115
- [4] Perera J. Anatomy of the origin of the deep femoral artery. Ceylon Med J. 1995; 40(4): 139-141, indexed in Pubmed: 8689700
- [5] Dixit D, Kubavat D, Rathod S, Patel M, Singel T. A Study of Variations in the Origin of Profunda Femoris Artery and Its Circumflex Branches. Int J Biol Med Res. 2011;2(4):1084-9
- [6] Sugawara Y, Sato O, Miyata T, Kimura H, Namba T, Makuuchi M. Utilization of the lateral circumflex femoral artery as a midway outflow for aorto-popliteal grafting: report of a case. Surg Today. 1998;28:967-970.
- [7] Fukuda H, Ashida M, Ishii R, Abe S, Ibukuro K. Anatomical variants of the lateral femoral circumflex artery: an angiographic study. Surg Radiol Anat. 2005;27(3):260-4.
- [8] Uzel M, Tanyeli E, Yildirim M. Anatomical study of the origin of lateral circumflex femoral artery in Turkish population. Folia Morphol (Warsz). 2008; 67(4):226-30
- [9] Prakash, Kumari J., Bhardwaj AK, Jose BA, Yadav SK, Singh G. Variations in the origins of the profunda femoris, medial and lateral femoral circumflex arteries: a cadaver study in the Indian population. Romanian Journal of Morphology and Embryology. 2010;51(1):167-70.
- [10] Sinkeet SR, Ogeng'o JA, Elbusaidy H, Olabu BO, Irungu MW: Variant origin of the lateral circumflex femoral artery in a black Kenyan population. Folia Morphol (Warsz). 2012,71:15- 18.
- [11] Manjappa T, Prasanna LC: Anatomical variations of the profunda femoris artery and its branches--a cadaveric study in South Indian population. Indian J Surg. 2014, 76:288-92. 10.1007/s12262-012-0677-3
- [12] Tzouma G, Kopanakis N A, Tsakotos G, et al. (April 28, 2020) Anatomic Variations of the Deep Femoral Artery and Its Branches: Clinical Implications on Anterolateral Thigh Harvesting. Cureus 12(4): e7867. DOI 10.7759/cureus.7867
- [13] Parasa Savithri. A rare variation of trifurcation of right femoral artery. International Journal of Anatomical Variations. 2013;6:4-6
- [14] Choi SW, Park JY, Hur MS, Park HD, Kang HJ, Hu KS, Kim HJ. An anatomic assessment on perforators of the lateral circumflex femoral artery for anterolateral thigh flap. J Craniofac Surg. 2007; 18: 866-871.