



**ORIGINAL RESEARCH PAPER**

**Plastic Surgery**

**GLOMUS TUMOUR OF HAND – FREQUENTLY MISSED DIAGNOSIS OF PAROXYSMAL PAIN – A CASE SERIES**

**KEY WORDS:** Glomus Tumor, Paroxysmal Pain, Cold Intolerance,

<b>Shailendra Singh*</b>	Associate Professor Department of Burns and Plastic Surgery, Smt NHL Municipal Medical College, Ahmedabad, Gujarat, 380059, India. Consultant, Zydus Hospital. *Corresponding Author
<b>Deepanjali Kalra</b>	Resident Doctors, Smt. NHL Municipal Medical College, Sardar Vallabhbhai Patel Institute Of Medical Sciences and Research, India.
<b>Himadri joshi</b>	Resident Doctors, Smt. NHL Municipal Medical College, Sardar Vallabhbhai Patel Institute Of Medical Sciences and Research, India.
<b>Manisha Singh</b>	Resident Doctors, Smt. NHL Municipal Medical College, Sardar Vallabhbhai Patel Institute Of Medical Sciences and Research, India.
<b>Charmi Bodra</b>	Resident Doctors, Smt. NHL Municipal Medical College, Sardar Vallabhbhai Patel Institute Of Medical Sciences and Research, India.
<b>Jay Adeshra</b>	Resident Doctors, Smt. NHL Municipal Medical College, Sardar Vallabhbhai Patel Institute Of Medical Sciences and Research, India.
<b>Rajvee Gohil</b>	Resident Doctors, Smt. NHL Municipal Medical College, Sardar Vallabhbhai Patel Institute Of Medical Sciences and Research, India.

**ABSTRACT**

**Introduction:** Glomus Tumour is a hamartoma consisting of neuroarteriovenous channels. Its main function is thermoregulation. It is mostly benign with rare malignant variation. It was first described by Wood in 1812. It is typically found in hand more commonly in subungual regions. Few are also reported from intra articular, intraneural or in toe nails also. Its classical clinical triad consists of pain, tenderness and intolerance to cold temperature. **Methods:** This is a study of 10 cases of Glomus tumours in hand. Which were operated by chief surgeon at multiple centres since year 2005. Patients were evaluated preoperatively with physical examination of cold intolerance and pain with Hildreth and Love's sign test. Diagnosis was confirmed by X-ray which sometimes shows erosion of adjacent phalanx, Ultrasonography which may pick up tumours up to 3 mm or more. MRI with contrast which picks up tumour upto 2 mm size also. MRI with contrast is a confirmatory diagnostic test. All patient underwent excision of tumour under regional or general anaesthesia, Torniquet and magnification under microscope. Six patients underwent excision with trans ungual, approach, two patients with volar approach and one patient with lateral subperiosteal approach. Histopathological reports helped to confirm the diagnosis and differentiate benign from malignant glomus tumours **Result:** Total 10 cases were reviewed. Six were subungual, three in volar aspect and one radial aspect of distal phalanx of fingertip. After excision, patient got relieved of excruciating pain and become asymptomatic. In long term follow up patients were satisfied functionally cosmetically and without any sign of recurrence. **Conclusion:** Total 10 cases done since 2005 are reviewed. Accurate Diagnosis with Physical examination and clinical triad, which was confirmed with diagnostic tools like Xray, USG and MRI . Surgery was done under torniquet and microscopic magnification to achieve complete extirpation of glomus tumour with satisfactory post operative result.

**INTRODUCTION**

Glomus tumours are hamartomas arising from glomus body, accounting for about 1%-5% of all hand tumours.[1] Glomus body is a contractile Neuromyoarterial structure found in the reticular dermis which controls the body temperature.

It can develop in any part of the body but most commonly found in upper extremities, mainly in distal phalanx of the fingers, especially in the subungual region [2,3]. Adult females are more prone in compare to males.

There is clinical triad of symptoms seen in glomus body tumour. Severe paroxysmal pain in the fingertips, tenderness, and cold intolerance.

Glomus tumours could be solitary or multiple. Solitary glomus tumour accompany pain and occur mainly in the distal extremities like sub ungual. Multiple glomus tumours are usually painless and can develop in any part of the body[3] , they are associated with Type 1 Neurofibromatosis.

Typical classical symptoms, clinical examination supported

by radiological investigations like x-ray, ultrasound and MRI confirms the diagnosis of glomus tumours.

Complete surgical excision of the tumour is the recommended treatment, in spite of proper excision chances of recurrence is always there.[3]

Here we are presenting case series of 10 patients with glomus tumor of hand. Which were managed since the year 2005 at multiple centres

**MATERIALS AND METHODS**

In our series of 10 patients, They were operated by our chief surgeon in last twenty years at multiple centres from 2004 to April 2024 .These patients were diagnosed as having solitary glomus tumour of one digit of hand. All of them were admitted with a chief complaint of pain in hand. Clinical examination revealed the paroxysmal severe pain over local site, tenderness and cold sensitivity in all patients.

All the patients underwent routine blood Investigations, x-ray and ultrasonography of local part. MRI with contrast was also

done to confirm the diagnosis.

After pre-operative fitness patients were taken for surgical excision of tumour under regional anaesthesia, and under a microscopic magnification and tourniquet. Pre operatively the specific location of the tumour was outlined three dimensionally. In six cases a typical Trans ungual approach was employed. In three cases volar approach was taken where tumours were located in the fingertip pulp. A lateral subperiosteal approach was taken in one patient.

In the transungual approach, a periosteal elevator was inserted between the fingernail and nail bed. The nail was

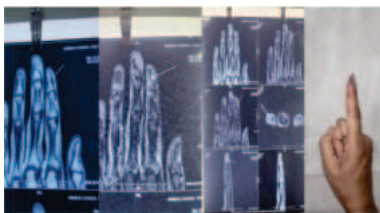
avulsed, with care taken not to damage the nail bed. Tumour exposed just below nailbed. The nail bed was incised longitudinally, and the tumour removed completely. Nailbed repaired with Vicryl 6-0. The nail plate repositioned and closed with nylon 4-0.

In volar approach an incision line was drawn directly over the site of tumour, and the tumour was excised and Skin closed with monocryl 5-0.

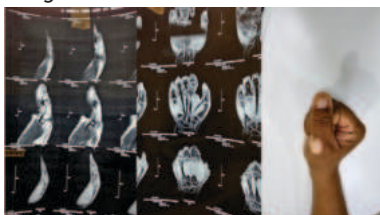
In lateral subperiosteal approach an incision line was drawn in the lower lateral side of the nail fold and the nail bed was raised to extract the tumour.

Case Nos	Age (yr)	Sex	Location	Size (mm)	Symptoms	Imaging study	Method	Result
1	40	Female	Left thumb, subungual	3	Pain, tenderness, Cold intolerance	X Ray,USG MRI	Transungual	Glomus tumor
2	31	Male	Left 5th finger, subungual	6	Pain, tenderness Subungual discolorations	X-ray, USG, MRI	Transungual	Glomangioma
3	38	Female	Right 3rd finger, subungual	4	Pain, tenderness Cold Intolerance	X-ray, USG, MRI	Transungual	Glomus tumor
4	42	Male	Right 2nd finger, subungual	6	Pain, tenderness, nail deformity/ discoloration	X-ray bone erosion,USG MRI	Transungual	Glomus tumor
5	31	Female	Right 5th finger, subungual	5	Pain, tenderness Cold Sensivity, Nail discoloration	X-ray, USG MRI	Transungual	Glomus tumor
6	26	Female	Left 4th finger, subungual	4	Pain, tenderness, Nail Deformity	X Ray,USG MRI	Transungual	Glomus tumor
7	39	Female	Left thumb, volar	8	Pain, tenderness Cold intolerance,	X-ray, USG MRI	Volar	Glomus tumor
8	33	Female	Right 3rd finger, volar	3	Pain, tenderness, cold sensitivity	X-ray, USG MRI	Volar	Glomus tumor
9	38	Male	Left thumb, volar	6	Pain, tenderness	X-ray Bone Erosion, USG MRI	Volar	Glomus tumor
10	39	Female	Right index finger, radial aspect	8	Pain, tenderness, dislocation,	X-ray Bone erosion, USG MRI	Lateral sub- periosteal	Glomus tumor

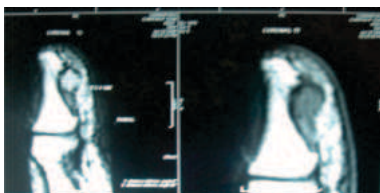
Cases done in last two decades.



**Figure 1:** Glomus Tumour of right Index finger distal phalanx, Radial Sub periosteal region. Lateral sub periosteal approach used for its surgical removal. Done in March 2024.



**Figure 2:** Glomus tumour in Sub ungual region Rt. Thumb. Trans Ungual Approach used for its Surgical Removal. Done in 2015.



**Figure 3:** Glomus seen in MRI Coronal Contrast Both T1 and T2 views present in in Volar region. Volar Approach was taken for its Surgical Removal. Done in July 2006

**RESULTS**

In our study out of ten patients seven (70%) were female and three (30%) were male. Only one (10%) patient has visible or palpable nodule. Four (40%) patients have nail deformity or bluish discoloration of nails. Three (30%) patients had bone erosion in x-ray findings. Ultrasonography showed lesion in five (50%) patients, which was confirmed by MRI with contrast. In remaining five patient findings were seen on MRI hand.

After surgery in all patients, the pain either disappeared or was alleviated and patients were satisfied with results. Patient were followed up on OPD basis. No recurrence seen during the follow-up period. In one (10%) patient post operatively Nail deformity was seen. Otherwise there were no associated significant complication with this operation.

**DISCUSSION**

Glomus body consists of Neuro-Arterio Venous anastomosis surrounded by smooth muscle fibs. Their main function is thought to be Thermoregulation. Anastomotic vascular channels are known as Sucquet-Hoyer canal, primary collecting vein, intraglomerular reticulum, and capsular portion.[5] Hyperplasia in any of these parts can lead to a tumour. It presents with the classic triad of symptoms, hypersensitivity to cold ie cold intolerance, paroxysmal pinpoint pain in the finger and tenderness at the local site of tumour [1,13]. Other symptoms include the distinctive subungual discoloration, hypoesthesia, atrophy, osteoporosis in the lesion, and autonomic disturbance such as Horner syndrome [2].

Various hypotheses are suggested for the cause of pain in glomus tumours the capsules of the tumours are sensitive to pressure, abundant mast cells in the tumours release substances like heparin, 5-hydroxytryptamin, and histamine,

making sensitivity to pain and cold receptors.

Glomus tumour usually occurs in areas rich in glomus bodies such as the subungual regions of digits, the deep dermis of the palm, wrist, forearm, and foot, intraosseous, and at the metacarpophalangeal joint. few cases of Intra Articular and Intra Neural Glomus are also reported [6,7].

Typically, glomus tumours occur as solitary lesions, most frequently seen in the fingertips at subungual region. They are encapsulated, usually subungual. In contrast, multiple tumours are unencapsulated, are rarely subungual, and have larger-shaped vascular spaces [1]. Multiple glomus tumours are often associated with Type I Neurofibromatosis [9] Mostly they are painless and asymptomatic and present earlier in life. Multiple glomus tumours have pink or purple nodal shape, and develop in young children or males. [11,12]

The differential diagnosis for solitary glomus tumour can be painful tumours like haemangioma, Neuroma, leiomyoma, eccrine spiradenoma, or gouty arthritis [3]. While multiple glomus tumours should be carefully differentiated from cavernous hemangioma which is tightly packed thin walled capillaries and blue rubber-bleb nevus syndrome [10].

There are various clinical diagnostic tests including Love's pin test, Hildreth's test, cold-sensitivity test and the trans-illumination test. In Love's pin test patient experience severe pain when the skin overlying the tumor is pressed with a pinhead, ballpoint pen, end of a paperclip, or Kirschner wire. Hildreth's test, in which, a tourniquet is applied inflated to 250 mm Hg along the arm to induce a transient ischaemia, withdrawal of pain from the affected area is noted by the patient. This can be attributed to the temporarily restricted blood supply as it is a vascular tumour.

This can be further substantiated by repeating the Love's pin test, which will be painless with inflated tourniquet and on removing the tourniquet, the patient will feel a sudden return of pain. The cold-sensitivity test is positive when immersing the hand in cold water elicits severe pain in and around the lesion [2,3]. Another less commonly used test is the trans-illumination test, in which light is passed through the finger pad; the tumour will appear as a red opaque image [3].

In spite of the classical presentation, delay in diagnosing these tumours for many years is a significant problem. It can be attributed to the variations in symptom presentation and sometimes obscure symptoms such as chronic pain and hypersensitivity. It is not uncommon that patients are easily misdiagnosed with conditions like neuropathic complaints, arthritis, or neuralgia and may undergo unsuitable treatment including sympathetic ganglionectomy or radicotomy. Moreover, its rarity along with lack of suspicion during examination of the patient with impalpable glomus tumour may explain the long delay to reach the correct diagnosis.

In imaging modalities simple X-ray, CT, angiography, and ultrasonography, MRI with contrast are used for more accurate diagnosis [2]. Radiographs show cortical thinning or erosive changes in the adjacent bone in some of the cases [14]. Ultrasonography can demonstrate the size, site, and shape of the tumour, but is subjective [15]. MR imaging is an excellent modality for detecting the glomus tumour as small as 2 mm and also helpful in making differential diagnoses. The glomus tumour in MRI is characteristically seen as a high signal central dot surrounded by a zone of lower signal intensity. It shows low signal intensity on T1-weighted images, high signal intensity on T2-weighted images. Gadolinium enhanced MRI is more useful [16].

Different treatment modality, such as sclerotherapy, laser, or surgical excision based on location and clinical presentation

[1] could be used. But complete surgical excision of the tumour is the only effective treatment. Excision must be complete, including the capsule, to avoid tumour recurrence [1,3]. Trans ungual or sub ungual, Volar or subperiosteal approach is used for Tumours in fingers. Total extirpation is performed after carefully avulsing the surrounding tissues of the tumours. If the tumours have penetrated in to the bones, bone curettage or partial excision is performed [2]. A bloodless field and Microscopic magnification are most important for fully removal of the tumor [1]. Nail deformity is an associated complication with this operation in the distal phalanx [1].

Histologically, glomus tumour is composed of varying proportions of glomus cells, blood vessels, and smooth muscle. Depending on the predominant component, there are three variants of glomus tumour namely:

- (1) Angiomatoid (glomangioma) with predominant blood vessels.
- (2) Solid (predominantly glomus cells)
- (3) Glomangiomyoma predominantly smooth muscle).

Multiple glomus tumours generally correspond to glomangioma. Although Glomus tumors are essentially benign, sarcomas can accompany in rare cases to form Glomangiosarcoma [10]

### CONCLUSION

Glomus tumours hamartomas occurring in hand are mostly in finger tip. It is benign with classical triad of clinical presentation of severe paroxysmal pain, cold intolerance and pin point tenderness. Most common site of occurrence is in subungual region, volar aspect or lateral aspect of distal phalanx. Imaging modalities like x-ray, ultrasound and MRI with contrast are helpful in detection of size, shape, location and number of tumours as well as differentiating it from other benign or malignant hand lesions. Complete meticulous surgical excision is treatment of choice, for which various approaches like trans ungual, volar or lateral approach are described. Recurrence or persistence of symptoms can occur either due to incomplete excision or recurrence of tumour over same or nearby site. Post-operative nail deformity is most commonly seen complication after conventional trans ungual approach. Post operative patient gets tremendous relief from excruciating paroxysmal pain and all the symptoms.

### REFERENCES

1. Nazerani, S., Motamedi, M. H., & Keramati, M. R. (2010). Diagnosis and management of glomus tumors of the hand. *Techniques in hand & upper extremity surgery*, 14(1), 8-13. <https://doi.org/10.1097/BTH.0b013e3181c767d4>
2. Lee, W., Kwon, S. B., Cho, S. H., Eo, S. R., & Kwon, C. (2015). Glomus tumor of the hand. *Archives of plastic surgery*, 42(3), 295-301. <https://doi.org/10.5999/aps.2015.42.3.295>
3. Morey, V. M., Garg, B., & Kotwal, P. P. (2016). Glomus tumours of the hand: review of literature. *Journal of clinical orthopaedics and trauma*, 7(4), 286-291. doi:10.1016/j.jcot.2016.04.006.
4. Drape, J. L., Idy-Peretti, I., Goettmann, S., Wolfram-Gabel, R., Dion, E., Grossin, M., ... & Bittoun, J. (1995). Subungual glomus tumors: evaluation with MR imaging. *Radiology*, 195(2), 507-515.
5. Kline, S. C., Moore, J. R., & Samuel, H. D. (1990). Glomus tumor originating within a digital nerve. *The Journal of hand surgery*, 15(1), 98-101.
6. Moor, E. V., Goldberg, I., & Westreich, M. (1999). Multiple glomus Tumors: a case Reports and review of the literature. *Annals of plastic surgery*, 43(4), 436-438.
7. Samaniego, E., Crespo, A., & Sanz, A. (2009). Key diagnostic features and treatment of subungual glomus tumor. *Actas Dermo-Sifiliográficas (English Edition)*, 100(10), 876-882.
8. Chatterjee, J. S., Youssef, A. H. K., Brown, R. M., & Nishikawa, H. (2005). Congenital nodular multiple glomangioma: a case report. *Journal of clinical pathology*, 58(1), 102-103.
9. Hazani, R., Houle, J. M., Kasdan, M. L., & Wilhelmi, B. J. (2008). Glomus tumors of the hand. *Eplasty*, 8.
10. Shin, D. K., Kim, M. S., Kim, S. W., & Kim, S. H. (2010). A painful glomus tumor on the pulp of the distal phalanx. *Journal of Korean Neurosurgical Society*, 48(2), 185.
11. Chen, S. H. T., Chen, Y. L., Cheng, M. H., Yeow, K. M., Chen, H. C., & Wei, F. C. (2003). The use of ultrasonography in preoperative localization of digital glomus tumors. *Plastic and reconstructive surgery*, 112(1), 115-119.
12. Theumann, N. H., Goettmann, S., Le Viet, D., Resnick, D., Chung, C. B., Bittoun, J., Chevrot, A., & Drapé, J. L. (2002). Recurrent glomus tumors of fingertips: MR imaging evaluation. *Radiology*, 223(1), 141-151. <https://doi.org/10.1148/radiol.2231010977>