

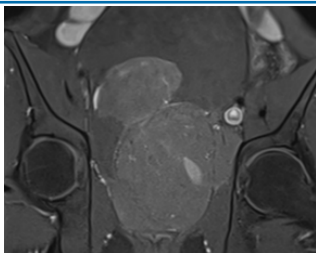


ORIGINAL RESEARCH PAPER	Radiology
RARE CASE OF INFLAMMATORY MYOFIBROBLASTIC TUMOR OF PROSTATE PRESENTING WITH HEMATURIA	KEY WORDS: Prostatic Inflammatory myofibroblastic tumor, Prostatic mesenchymal tumor

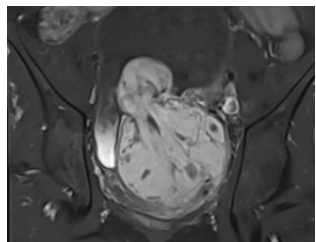
Dr. Mreega Sheth	3 rd year Radiology Resident.
Dr. Rutvik Patel	2 nd year Radiology Resident.
Dr. Chirag Dewani	2 nd year Radiology Resident.

ABSTRACT	Adenocarcinoma and its variants constitute the most common neoplasm of the young adult prostate, accounting for approximately 95% of all malignant tumors. In contrast to epithelial tumors of the prostate, mesenchymal neoplasms of the prostate are rare. Inflammatory myofibroblastic tumor (IMT) of the prostate is one of the uncommon benign neoplasm that can mimic prostate cancer clinically and radiologically. Given its rarity and potential for misdiagnosis, understanding the imaging features of prostatic Inflammatory myofibroblastic tumor is crucial for accurate diagnosis.
----------	---

<p>INTRODUCTION</p> <p>Mesenchymal tumors of the prostate and seminal vesicles are typically large at presentation. Most patients present with nonspecific symptoms, abnormal digital rectal examination findings, and normal prostate-specific antigen (PSA) level. Imaging features of the diverse spectrum of mesenchymal tumors are sparsely addressed in the radiology literature. Although some tumors display imaging findings that suggest the diagnosis, accurate diagnosis is critical for optimal treatment planning—it warrants histopathologic examination. Precise diagnosis is challenging owing to the rarity of the tumors, the small size of biopsy specimens, and the subtle histopathologic differences between various spindle cell lesions.</p> <p>Inflammatory myofibroblastic tumor is a mesenchymal neoplasm of intermediate biologic potential with a propensity to involve the lungs, peritoneum, or retroperitoneum. It primarily affects children and young adults. About one-third of patients with IMT may present with a systemic inflammatory syndrome characterized by fever, weight loss, and elevated serum inflammatory markers. The urinary bladder is the most common target site within the genitourinary tract. Up to 75% of IMTs demonstrate ALK gene rearrangement at chromosome 2p23. Prostate IMT has been reported at various ages (21–83 years) and is more common in the elderly (>60 years). At histopathologic analysis, prostate IMT consists of a proliferation of spindle-shaped myofibroblasts in a background of variable inflammation and prominent vascularity. ALK protein is commonly expressed at immunohistochemistry.</p> <p>Imaging features are varied, reflecting variable amounts of active inflammation, fibrosis, and cellular infiltration. IMT is generally hypointense on T1-weighted images and may show mixed heterogeneous T2 hypo- or hyperintensity, depending on the amount of fibrosis and active inflammation present. Areas of high cellularity typically show significant diffusion restriction. At contrast-enhanced CT and MRI, IMT may show avid homogeneous or heterogeneous enhancement. Delayed progressive enhancement may be noted if florid fibrosis is predominant.</p> <p>Differential Diagnosis: Leiomyoma of prostate Prostatic rhabdomyosarcoma Solitary fibrous tumor GIST of prostate</p> <p>Case Study: A 28-year male patient presented with complaints of Haematuria, burning micturition and lower abdominal pain</p>	<p>for 1 month. Patient has been referred to radiology department for MRI evaluation.</p> <p>Imaging Findings : The prostate appears diffusely enlarged with multiple cystic areas within and measures approx. 65 cc and shows approximately 53 cc median lobe projecting into the urinary bladder with intravesical extension.</p> <p>Entire prostate gland shows heterogenous signal intensity lesion with pseudocapsule with bunch of grapes appearance.</p> <p>The lesion appears hypointense on T1 WI, heterogeneously hyperintense on T2 WI.</p> <p>The lesion shows few patchy areas of diffusion restriction on DWI images.</p> <p>On post contrast images it shows heterogenous and avid early post contrast enhancement.</p> <p>Histopathological Findings: On histological analysis the lesion appears to be suspicious for prostatic stromal tumor probably Inflammatory Myofibroblastic Tumor.</p>  <p>On T2 coronal images, it appears heterogeneously hyperintense with few cystic areas within.</p>  <p>On DWI images, it shows multiple foci of diffusion restriction.</p>
---	---



On T1 fat saturated images, it appears heterogeneously hypointense.



On T1 fat saturated post contrast images, it shows avid enhancement.

CONCLUSION :

Cross-sectional imaging modalities, particularly MRI, permit detection, accurate localization, and determination of extent of spread of benign and malignant mesenchymal tumors of prostate like Inflammatory myofibroblastic tumor.

REFERENCES :

1. <https://radiopaedia.org/articles/inflammatory-myofibroblastic-tumour>
2. Andreou A, Whitten C, MacVicar D, Fisher C, Sohaib A. Imaging appearance of sarcomas of the prostate. *Cancer Imaging* 2013;13(2):228–237.
3. McKenney JK. Mesenchymal tumors of the prostate. *Mod Pathol* 2018;31(S1):S133–S142.
4. Kitzing YX, Prando A, Varol C, Karczmar GS, Maclean F, Oto A. Benign Conditions That Mimic Prostate Carcinoma: MR Imaging Features with Histopathologic Correlation. *RadioGraphics* 2016;36(1):162–175.
5. Gaudin PB, Rosai J, Epstein JI. Sarcomas and related proliferative lesions of specialized prostatic stroma: a clinicopathologic study of 22 cases. *Am J Surg Pathol* 1998;22(2):148–162.