



## ORIGINAL RESEARCH PAPER

## General Surgery

### STAPLER HAEMORRHOIDECTOMY- A STEP FORWARD IN SURGICAL MANAGEMENT OF HAEMORRHOIDS.

#### KEY WORDS:

**Dr Narayan Sanap**

Associate Professor, Dept of General Surgery, MGM Medical College and Hospital, Aurangabad, Maharashtra, India.

**Dr Satyajeet Pathrikar**

Associate Professor, Dept of General Surgery, MGM Medical College and Hospital, Aurangabad, Maharashtra, India.

**Dr Nikhil Chauhan**

Assistant Professor, Dept of General Surgery, MGM Medical College and Hospital, Aurangabad, Maharashtra, India.

**Dr Amit Lathoriya**

Junior Resident, Dept of General Surgery, MGM Medical College and Hospital, Aurangabad, Maharashtra, India.

#### ABSTRACT

**Introduction :** Haemorrhoids are the most common benign perianal disease which can impede quality of life. Grade 3 and grade 4 haemorrhoids need surgical intervention. The traditional approach for surgical management is open haemorrhoidectomy but unfortunately is associated with complications like faecal incontinence, bleeding, infections etc. A constant search for a better surgical method has led to the modern technique of stapler haemorrhoidectomy. In this study we aim to study the outcomes of stapler haemorrhoidectomy in terms of ease of use, intra-operative complications and morbidity. **Material and Methods:** A prospective single arm study with n=50 underwent stapler haemorrhoidectomy. Grade 2,3,4 uncomplicated haemorrhoids were included in the study. after anaesthetic fitness, patients underwent stapler haemorrhoidectomy. Postoperative pain scores, bleeding was noted and after discharge patients were followed up on 10th day, 3rd month and 6th month. Complications like anal stenosis, stricture, sepsis, pain were noted. **Results:** out of the 50 cases, 38 were male while 12 were female with an average age of 41 year (range 25-61 years). Most common symptoms were bleeding (80%), prolapsed (70%), pain (8%), soiling (4%). Patients presented with grade 2 (14%), grade 3(56%), grade 4(70%) haemorrhoids. The average operative time was 27.1 minutes. Postoperatively, 90% cases had mild pain while 10 % had moderate pain. 4 patients had bleeding with 3 having minor bleeding. After discharge, most of the patients resumed work within 3 days. Only 1 patient had recurrence and none had sepsis or stricture. **Conclusion:** It has been concluded that the staplers are a novel way of doing hemorrhoidal surgeries and has increased the horizons of hemorrhoidal surgery to a great extent. However, technical skills, good on table judgment, intelligence and knowledge of all possible pitfalls and errors of stapling are required to achieve optimal results.

#### INTRODUCTION

Haemorrhoids are symptomatic vascular cushions which prolapse due to disruption of suspensory ligaments leading to vascular engorgement and eventual bleeding. [1,2,3] grade 3 and 4 eventually need surgical management for symptomatic relief. Millions of Indians have haemorrhoids and many will require surgery. The haemorrhoidectomy technique namely Milligan-Morgan and Fergusson are associated with severe pain, post-operative haemorrhage and small risk of incontinence [4,5]. A need for less painful techniques leads novel techniques like Haemorrhoidal artery ligation operation (HALO) and stapler Haemorrhoidopexy. These are being used but evidence supporting these newer modalities are lacking.

Stapler Haemorrhoidopexy simply excises a ring of rectal mucosa above the pathological rectal mucosa while traditional approach is to excise haemorrhoidal tissue, anoderm and perianal skin. Initially the anal canal is dilated and a purse string suture is placed above the dentate line. The anvil is inserted and positioned above the purse string sutures. The anvil and stapler are attached and the stapler is fired. A circular ring containing haemorrhoidal tissue and proximal rectal mucosa is excised and remaining anal and rectal mucosa are anastomosed. [6]

Though recent evidences [7,8,9] suggest that this technique is superior in terms of ease of use and post-operative pain and operative time, long term evidences are still lacking. This study aims to determine the efficacy of stapler haemorrhoidectomy in terms of ease of use, operative time and complications.

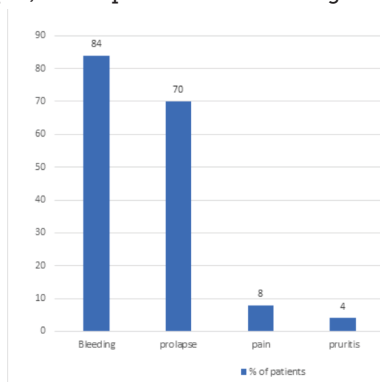
#### MATERIALS AND METHODS

In this prospective single arm interventional study over a period of two years, 50 patients with grade II, grade III and grade IV uncomplicated haemorrhoids were included in the study. complicated haemorrhoids, grade I haemorrhoids, associated malignancy was excluded from the study. history of all patients was taken and clinical examination by per rectal examination and proctoscopy was performed for proper diagnosis. In case of suspicion of malignancy, patient underwent colonoscopy to rule out malignancy. Once included in the study the patients underwent anaesthetic fitness for stapler haemorrhoidectomy after consent. Preoperatively patients were given per rectal enema prior to surgery. Intraoperatively, the operative time was counted from after induction of anaesthesia to up to the end of the procedure. Postoperatively patients were given adequate analgesics and any complications like hematoma, retention, bleeding and pain and time of ambulance was noted. Patients were discharged after initial monitoring and followed up on 10<sup>th</sup> day, 3<sup>rd</sup> month and 6<sup>th</sup> month for late complications like stricture, recurrence, sepsis, and time to re-join work. Throughout the study pain score was calculated using visual analogue pain scale and designated as mild (score 0-2), moderate (score 3-6) and severe (score 7-10).

#### RESULTS

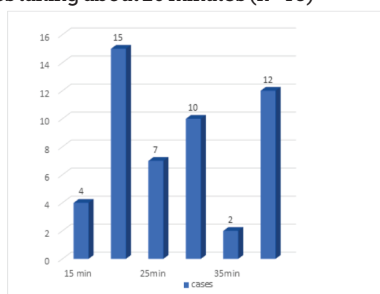
Out of the 50 patients that underwent stapler Haemorrhoidectomy, 38 (76%) were male and 12 (24%) were female. The mean age of presentation in the study was 43.38 years with a range of 26-65 years. Maximum number of patients belonged to 41-50 years of age (n=15) followed by 51-60 years (n= 13). Constipation was the most common associated history ( n=22) followed by fissure in ano (n=6). Grade III haemorrhoids (n=28) was the most common grade followed

by grade II (n=15) and then by grade IV (n=7). As per symptomatology 84% presented with bleeding while 70% had prolapse, 8% had pain and 4% had soiling and pruritis



Out of the 50 cases, 42 cases underwent elective stapler haemorrhoidectomy while 8 cases underwent emergency due to bleeding (n=6) and pain (n=4)

The average operative time after induction of anaesthesia till completion of surgery was 27.1 minutes with most of the procedures taking about 20 minutes (n=15)

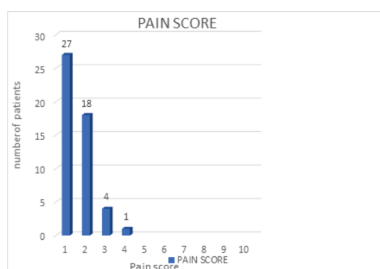


#### Postoperative Outcomes

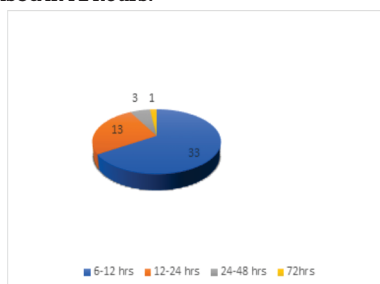
In early complications only 6% had retention of urine, 8% had bleeding, and 2% had hematoma.

Out of the 4 patients that had bleeding 3 had mild bleed and 1 had moderate bleed who was on anticoagulation.

90% had a mild pain score (n=45) while 5 patients (10%) had moderate pain score. None of the patients had pain score above 5.

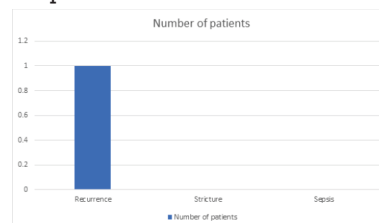


Time of ambulation: 33 patients (66%) were mobilised in 6-12 hours while 13 patients (26%) were mobilised in 12-24 hours. Only 3 patients were mobilised in 24-48 hours while only 1 was mobilised in 72 hours.

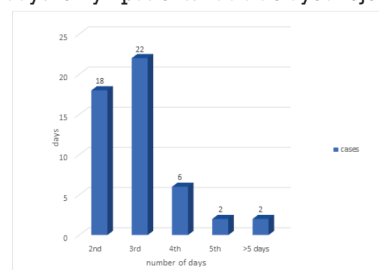


#### Follow Up Outcomes

Only 2% (1 patient) had recurrence while none of the patients had sepsis or stricture formation.



The time to re-join work was 3 days for 22 patients, while 2 days in 18 days. only 2 patients had a delayed rejoining



#### DISCUSSION

The mean operative time was 27 minutes in this study which is lesser than conventional operative technique. This can be shortened by adequate surgeon training and incorporating this technique in routine use.

The most important advantage of this technique is reduction in post-operative pain as compared to conventional technique. The conventional method involves removal of the anoderm which is extremely painful. In this study only 10% patients had moderate pain post operatively. Stapler haemorrhoidectomy involves removal of circular rectal and haemorrhoidal tissue above the dentate line which minimizes pain. There are several explanations for this postoperative pain. Use of circular stapler results in the reduction of vascular supply to the haemorrhoids, circumferential excision of the redundant rectal mucosa, reduction and fixation of prolapsed hemorrhoidal tissue, and preservation of the anal transitional zone. In some patients the pain may be due to thrombosis of the haemorrhoidal tissue left behind after the procedure. Where the prolapse has a large circumference, the tendency is to place the stapled line too close to anal verge in an attempt to incorporate more redundant rectal and haemorrhoidal tissues into the stapler. However, this results in the partial excision of sensitive anoderm, with the effect of significant postoperative pain. Lastly, inappropriate placement of purse string suture may result in incorporation of rectal muscle and nerves, with resulting pain after surgery.

In this study only 4 patients had bleeding. In stapled method bleeding occurs at the staple line which can be managed by submucosal adrenaline injection using proctoscopy. The newer PPHO3 which has a closed staple height of 0.75mm, postoperative bleeding may be reduced owing to an increase in compression on rectal mucosa and blood vessels.

Acute urinary retention is also common after haemorrhoidectomy [10]. This is usually because of a combination of anaesthesia, postoperative pain and anxiety. In this study 6% patients had acute retention of urine.

Formation of anorectal stricture is a known complication after stapled haemorrhoidectomy, with a reported incidence of above five percent. It has been postulated that the occurrence of stricture is due to the placement of the purse string, and thus the anastomosis, below the accepted 4 cm from the anal verge. Most stricture formation occurred very early in the postoperative period. In this study no patient had stricture formation. Digital dilatation can be easily performed

when patients are reviewed early after surgery, usually about two weeks. At that time the fibrous tissue forming the stricture are soft and easily disrupted. With this, only a small percentage of patients developed symptomatic stricture that required surgical intervention. The majority of these patients developed significant stricture within the first few months after surgery. Simple stricturoplasty or anal dilatation is all that necessary for anorectal stricture formation after stapled haemorrhoidectomy.

Stapled haemorrhoidectomy is a radical procedure that aims to remove all the haemorrhoidal vasculature yet recurrence can occur. In the current series, this may be because of incomplete transaction of the haemorrhoidal vessels, poor fixation of the anal cushion to the anorectal musculature or even neovascularization. We recommend conventional surgery for recurrence as these patients usually present with single haemorrhoidal prolapse. In selected patients, repeated stapled haemorrhoidectomy may be effective.

Many individual studies Rabriya S et al, Khalil K H et al, Shalaby R et al, Ng K-h et al, Plocek, Margarete D et al showed that stapler haemorrhoidectomy is a safe and effective procedure for grade 3 and 4 haemorrhoids. Similarly, recent review of Ruan et al suggests this to be an effective measure for treatment of haemorrhoids.

## CONCLUSION

Stapler haemorrhoidectomy is a minimally invasive technique which is simple to perform with advantages of reduced operative time as compared to open techniques. Reduction in post operative pain, reduced bleeding complications, reduced incontinence lead to a early recovery and reduced hospital stay and earlier resumption to work. Despite of its various advantages this technique is prohibitively costly

Based on observations in this study, it has been concluded that the staplers are a novel way of doing hemorrhoidal surgeries and has increased the horizons of hemorrhoidal surgery to a great extent. However, technical skills, good on table judgment, intelligence and knowledge of all possible pitfalls and errors of stapling are required to achieve optimal results.

## REFERENCES

1. Baily and Love's Short Practice of Surgery 24<sup>th</sup> Edition Pp 1260.
2. Schwartz 'Principle of Surgery 8<sup>th</sup> edition Pp 1102-1103.
3. Maingot's Abdominal Operations 11<sup>th</sup> edition.
4. Stapled Vs Excisional Hemorrhoidectomy : Long term Results of Prospective Randomized Trial Hetzer FH Demartines N. Handschin Archives of Surgery March 2002 Vol. 137 pp 337-340
5. Randomized Clinical trial of Stapled hemorrhoidectomy versus Milligan - Morgan hemorrhoidectomy Shalaby R Desoky A. , British Journal of Surgery 2001
6. Basadanis G, Harlaftis N, Michalopoulos A. Surgical treatment of haemorrhoids with use of the circular stapler and open haemorrhoidectomy: a comparative study. Tech Coloproctol. 2000;4:137-140.
7. Mehigan BJ, Monson JR, Hartley JE. Stapling procedure for haemorrhoids versus Milligan-Morgan haemorrhoidectomy: randomised controlled trial. Lancet 2001;355:782-785
8. Beattie G, Loudon M. circumferential stapled anoplasty in management of haemorrhoids and mucosal prolapse. Colorectal Dis. 2001;2:170-175
9. Pope V, Doran H, Fearn S, Brough W, Wilson M. Randomised controlled trial comparing quality of life after open haemorrhoidectomy (OH) plus stapled anoplasty (SA). Dis Colon Rectum 2001;44:A8
10. Singer MA, Cintron JR, Fleshman JW et al. Early experience with stapled haemorrhoidectomy in United States. Dis Colon Rectum 2002;45:360-9.