



**ORIGINAL RESEARCH PAPER**

**Paediatric Surgery**

**UMBILICAL DISCHARGE IN NEONATES: MORE THAN WHAT MEETS THE EYE**

**KEY WORDS:** umbilical, neonates, vitellointestinal duct

**Dr. Kashyapi Bala Upasana Thondepu**

Postgraduate, General Surgery Sri Ramachandra Institute Of Higher Education And Research Porur, Chennai.

**Prof. Prakash Agarwal**

Professor, Department Of Pediatric Surgery Sri Ramachandra Institute Of Higher Education And Research

**Prof. Madhu**

Hod, Department Of Pediatric Surgery Sri Ramachandra Institute Of Higher Education And Research

**ABSTRACT**

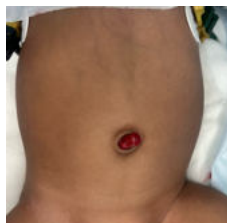One month old child was brought to the OPD with complaints of persistent discharge from the umbilicus and a mass protruding the umbilicus. On examination, small suspicious sinus opening was noted. Hence a contrast dye study was done and free flow of dye was noted into the small bowel with feeding tube entering the small bowel. So, the child was diagnosed to have a completely patent vitellointestinal duct. Anesthesia fitness was obtained and the patient was taken up for resection anastomosis of small bowel. Post operatively child was comfortable and discharged on POD-4.

**BACKGROUND:**

The abdomen is formed due to differential growth that causes ventral flexion and lateral folding of trilaminar embryo around 4 weeks of gestation. The Yolk sac is ventral in position. It is divided into extra-coelomic and intra-coelomic parts but the correction is maintained by vitelline or omphalomesenteric duct, which usually disappears by 5-7 weeks of gestation. Failure of regression of this connection has various presentations, ranging from only mass protruding from the umbilicus to severe fluid and electrolyte loss that causes failure to thrive.

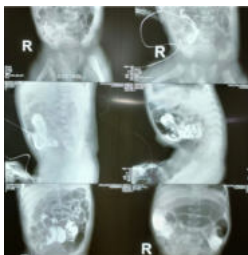
**Case Presentation:**

A one-month-old child was brought to the OPD with complaints of persistent discharge and swelling at the umbilicus since birth. The child was otherwise comfortable. No complaints of vomiting, passing stools, tolerating breastfeeds. On examination, vitals were stable. The abdomen was soft, and a 1 x 1 cm reddish mass was noted protruding from the umbilicus which was not reducible. A small sinus opening was noted over the mass. The surrounding skin was normal



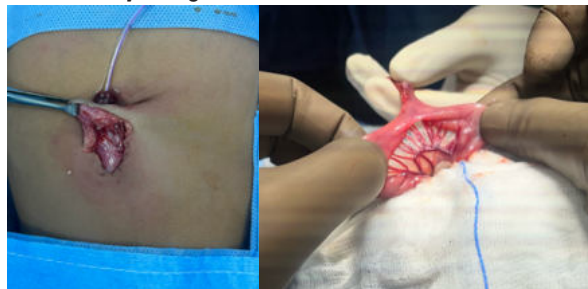
**Investigation:**

Blood investigations were within normal limits. A feeding tube was passed through the sinus opening and was noted to pass intra-abdominally. Contrast was injected via the tube and dye study was done which showed free flow of contrast into the bowel (Fig.1).



**Treatment:**

The baby was taken up for surgery after admission. Infra umbilical smile incision was made. Feeding tube was inserted and continuity with bowel was noted. Dissection was done, patent vitello intestinal duct was noted (Fig.2). Vitelline artery was identified and ligated. Small bowel resection and anastomosis were done. Omphaloplasty was done. Baby passed stools on POD-3 then started on breastfeeds, tolerated well and discharged on POD-4. Postoperative specimen histopathology report showed duct with ulceration and inflammatory changes.



**DISCUSSION:**

When a baby is brought with complaints of mass protruding per abdomen, the most common suspicion would be an umbilical granuloma. The incidence of umbilical granuloma in newborns is 3.83% (1). Remnants of the vitello intestinal duct can present as an umbilical polyp, cyst, sinus, or Meckel's diverticulum and can lead to various complications (2). A completely patent omphalo mesenteric duct is the rarest presentation with 0.0063-0.067% (3). As the management of these conditions is very different, careful history and examination is extremely important in the assessment of any umbilical mass.

**REFERENCES:**

- Iijima S. Umbilical Granuloma: Frequency, Associated Factors, 10-Year Treatment Trends, and Effectiveness at a Single Hospital in Japan. J Clin Med. 2023 Sep 21;12(18):6104. doi: 10.3390/jcm12186104. PMID: 37763044; PMCID:PMC10531942.
- AITKEN J. Remnants of the vitello-intestinal duct; a clinical analysis of 88 cases. Arch Dis Child. 1953 Feb;28(137):1-7. doi: 10.1136/adc.28.137.1. PMID: 13031688; PMCID:PMC1988648.
- Agrawal S, Memon A. Patent vitellointestinal duct. BMJ Case Rep. 2010 Oct 6;2010:bcr1220092594. doi: 10.1136/bcr.12.2009.2594. PMID: 22778111; PMCID:PMC3029414.