PARIPEX - INDIAN JOURNAL OF RESEARCH | Volume - 14 | Issue - 03 | March - 2025 | PRINT ISSN No. 2250 - 1991 | DOI : 10.36106/paripex

ORIGINAL RESEARCH PAPER

Pathology

A RARE CASE OF METASTASIS OF MALIGNANT CELLS IN CSF IN 80 YEARS OLD FEMALE

KEY WORDS: Cervical smear, Pap smear, Benign and Malignant

Dr. Ravi Bhimani Resident, Department of Pathology

Dr. Neelaba K. Mori Associate Professor, Department of Pathology

Dr. Nisha G. Raval Professor and Head of Department of Pathology

Dr. Bhavdish Pandya Assistant Professor, Department of Pathology

Dr. Kirti Jetapariya Assistant Professor, Department of Pathology

ABSTRACT

The majority of leptomeningeal spread by cerebrospinal fluid (CSF) occurs secondary to breast cancer, lung cancer, and melanoma, a wide variety of malignancies have been reported as primary sources. Metastatic spread into the CSF represents a severe complication of malignant disease with a poor prognosis. Although early diagnosis is crucial, broad spectrums of clinical manifestations and pitfalls of magnetic resonance imaging (MRI) and CSF diagnostics can be challenging. [1]

INTRODUCTION

Leptomeningeal metastasis is caused by malignant cells infiltrating the cerebrospinal fluid (CSF) by hematogenous spread, endo or perineural dissemination along peripheral nerves, or by direct expansion of parenchymal cerebral metastases. Analysis of CSF cells is essential to exclude alternative diagnoses such as infectious or autoimmune diseases which can cause similar neurological symptoms and MRI findings [2-3]. Furthermore, CSF parameters such as total protein and lactate levels have been demonstrated to be prognostic factors for the disease course of leptomeningeal metastasis [4-6]. This research examines how cerebrospinal fluid (CSF) findings, clinical symptoms, and MRI results are interconnected in patients diagnosed with leptomeningeal metastasis associated with various cancers. The detection of cancerous cells in the CSF suggests a grim prognosis, with an average life expectancy of 2 to 6 months. Therefore, prompt diagnosis is crucial for maintaining patients' quality of life and improving survival rates through treatments like intrathecal chemotherapy, systemic chemotherapy, and radiation therapy.

Case History

- An 80-year-old female patient presented at medicine OPD with C/O Headache and disorientation.
- K\c\o Parkinson's disease and the patient is on medication.
- No H\o of fever, convulsion, or neck rigidity.

MRI Brain– Multiple confluent hyperintense areas involving bilateral basal ganglia, thalami, periventricular deep white matter, left hemipenes, right temporal lobe, bilateral frontal lobe, and centrum semiovale on T2W & FLAIR (Fazeka's grade III) image—cerebral and cerebellar atrophic changes.

XRAY Chest (AP)- Multiply scattered radio-opacities noted in bilateral lung fields. Patchy in homogenous radio-opacity was noted in the left mid-lung zone. Bronchiectatic changes were noted in the bilateral mid-lower lung zone. Old healed calcified lesions were noted in bilateral lung fields.

CECT thorax- Neoplastic etiology involving the anterior segment of the left upper lung zone with multiple nodular lung metastases.

BIOCHEMISTRY

Nature of Specimen	CSF		
ADA	4.1	U/L	Serum/Plasma : 4-24 U/L Pleural,Pericardial and Ascitic Fluid Normal : < 40 U/L Suspect for MTB : >40 - <60 U/L Strong Suspect for MTB >60.0 U/L C.S.F. :- Normal : < 10.0 U/L Positive : >10.0 U/L (Tuberculous Meningitis)
TOTAL PROTEIN			
Total Protein	6.15	gm/dL	6.4 - 8.2
Albumin	2.52	gm/dL	Adult : 3.4 - 5.0
Globulin	3.63	gm/dL	2.7 - 3.5
A/G Ratio	0.69		2:1

CEREBRO-SPINAL FLUID

Physical Examionation			
Quantity	01	ml	
Colour	Colourless		
Appearance	Clear		
Cobweb	Absent		
Blood	Absent		Absent
Chemical Examination			
CSF Protein	117.9	mg/dL	15 - 45
CSF Glucose	22	mg/dL	40-70
Microscopic Examination			
Total Cells	40	/cmm	100 - 200
Polymorphs	05	%	
Lymphocytes	85	%	
Monocytes	10	%	2-10
Other Cells	atypical cells	%	
R. B. C.	Occasional		
Gram Stain	No organism seen		
Z-N Stain	No Acid Fast Bacilli Seen		

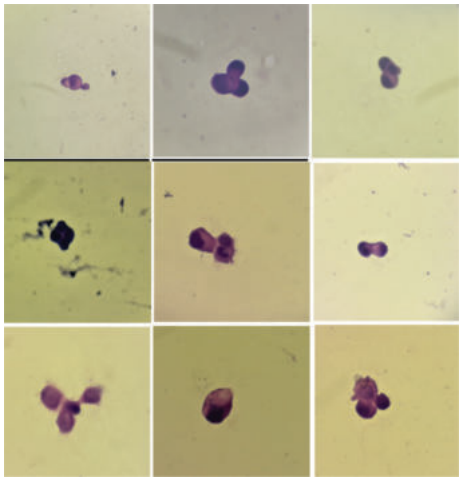

Cytology Report

Type of Specimen- CSF, 1 ml, clear, colorless

Microscopic Description- Centrifuged cytology smears are cellular show clusters of atypical cells having a high N:C ratio, pleomorphism and hyperchromasia. Cells show pushed nuclei. The background shows few inflammatory cells.

Diagnosis- Atypical cells favor the diagnosis of malignancy.

DISCUSSION

- There are three main approaches to identifying leptomeningeal metastasis and the dissemination of tumor cells within the cerebrospinal fluid (CSF): CSF cytology, neurologic assessment, and imaging examinations of the neuraxis. Additional detection methods include immunocytochemistry, flow cytometry, PCR/genetic analysis, noncellular biomarkers, and magnetic iron oxide nanoparticles (MIONs), as well as quantum dots.
- The observed leptomeningeal enhancement on MRI is likely due to the leakage of the contrast agent resulting from damaged blood vessels in the pia mater.
- Research has also shown that the enhancement of the leptomeninges with contrast is influenced by the type of malignant cells present in the CSF. Tumor cells with epithelial characteristics are more prone to adhere to the meninges and form layers of neoplastic tissue, which can be identified through MRI.
- The incidence of leptomeningeal contrast enhancement on MRI is greater in patients with solid tumors (61%) compared to those with blood cancers (33%). This lower sensitivity of MRI in detecting leptomeningeal metastasis from hematological malignancies aligns with previous studies, which suggest that lymphoma or blast cells are more likely to remain suspended in the CSF rather than attaching to the meninges.
- Dysfunction of the blood-CSF barrier in leptomeningeal metastasis is most likely attributable to decreased absorption of CSF due to blockages caused by malignant cells. As a result, hydrocephalus commonly occurs in patients with leptomeningeal metastasis and is often a life-threatening complication that necessitates neurosurgical intervention.

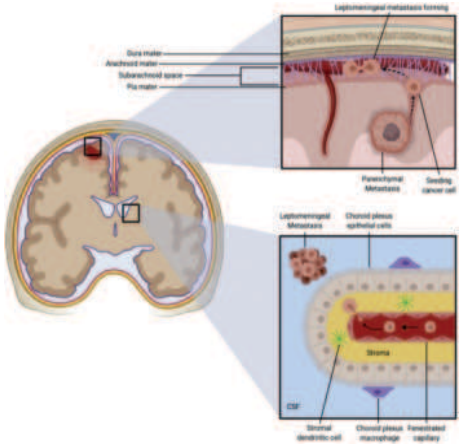

Potential Routes of Spread to Leptomeninges

CONCLUSION

The evaluation of cerebrospinal fluid (CSF) should be part of the diagnostic process for leptomeningeal metastasis, particularly in cases where MRI does not reveal any evidence of such metastasis. Performing CSF cytology is essential irrespective of the cell count in the CSF and can be vital even if there is no suspicion of leptomeningeal metastasis.

REFERENCES

1. https://www.ncbi.nlm.nih.gov/pmc/articles/PMC6710356/
2. Freilich RJ, Krol G, DeAngelis LM. Neuroimaging and cerebrospinal fluid cytology in the diagnosis of leptomeningeal metastasis. Ann Neurol. (1995) 38:51–7. 10.1002/ana.410380111 [PubMed] [CrossRef] [Google Scholar] [Ref list]
3. Chamberlain MC. Neoplastic meningitis. Oncologist. (2008) 13:967–77. 10.1634/theoncologist.2008-0138 [PubMed] [CrossRef] [Google Scholar] [Ref list]
4. Herrlinger U, Forschler H, Kuker W, Meyermann R, Bamberg M, Dichgans J, et al.. Leptomeningeal metastasis: survival and prognostic factors in 155 patients. J Neurol Sci. (2004) 223:167–78. 10.1016/j.jns.2004.05.008 [PubMed] [CrossRef] [Google Scholar] [Ref list]
5. Chamberlain MC. Leptomeningeal metastasis. Curr Opin Oncol. (2010) 22:627–35. 10.1097/CCO.0b013e32833de986 [PubMed] [CrossRef] [Google Scholar] [Ref list]
6. Leal T, Chang JE, Mehta M, Robins HI. Leptomeningeal metastasis: challenges in diagnosis and treatment. Curr Cancer Ther Rev. (2011) 7:319–27. 10.2174/157339411797642597 [PMC free article] [PubMed] [CrossRef] [Google Scholar] [Ref list]