



**ORIGINAL RESEARCH PAPER**

**Radio-Diagnosis**

**ALL ADNEXAL MASSES ARE NOT ECTOPICS, CLUES FOR DIAGNOSIS OF TUBAL ECTOPIC – OUR EXPERIENCE**

**KEY WORDS:**

**Dr Susmitha.G**

MD,DNB Radiology Associate Professor, Department Of Radiodiagnosis Jr Medical College And Hospital, Tamilnadu, india

**Dr Gorantla Praveen\***

MD Radiology, Assistant Professor Department Of Radiodiagnosis Jr Medical College And Hospital, Tamilnadu, india\*Corresponding Author

**Dr Manchi Nikhilesh**

Senior Registrar, Anesthesia And Critical Care Kims, Kondapur, Hyderabad

**INTRODUCTION :**

Ectopic pregnancy accounts for approximately 2% of all pregnancies and is the most common cause of pregnancy-related mortality in the first trimester. Initial evaluation consists of hormonal assays and pelvic ultrasonography. A history of pelvic pain, vaginal bleeding along with an abnormal human chorionic gonadotropin level should trigger an evaluation for an ectopic pregnancy. The fallopian tube is the most common location for an ectopic pregnancy.

This article highlights the importance of diagnosing tubal ectopic pregnancy and to rule out false positive diagnosis. Diagnosis of ectopic pregnancy is always confusing and false positive diagnosis always cause unnecessary anxiety to the patient. Here in our unit Kompally, we created an ectopic pregnancy scoring system to rule out unnecessary false positive results and to increase the sensitivity and specificity of the diagnosis. Vaginal bleeding in the first trimester has wide differential diagnoses, the most common being a normal early intrauterine pregnancy, with other potential causes including spontaneous abortion and ectopic pregnancy. Knowledge of the different locations of ectopic pregnancy is of utmost importance, in which ultrasound imaging plays a crucial role. This article highlights importance of multiple sonographic findings taking into consideration to improve the accuracy of the diagnosis and also to counsel the couple properly.

**QUESTIONNAIRE FOR DIAGNOSING ECTOPIC**

In case of Urine Pregnancy Test Positive status or absent doubling of Beta-HCG with no Intrauterine gestational sac. Questions to be raised.

1. Does the patient have clinically significant symptoms ? A) Present /B)Absent.

2.What is the status of endometrium ?

A) Normal homogeneous appearance / Trilaminar appearance. B) Thickened / Decidual reaction / Pseudosac.

3. Is corpus luteum seen in any of the ovaries separately from the adnexal mass.

4. Are there adnexal masses – a) Simple – Hydrosalpinx / Paraovarian cyst / Simple exophytic cyst / Exophytic corpus luteum. b) Complex adnexal mass.

5. Peritoneal fluid with echoes / Hemoperitoneum – a) Present / b) Absent.

**Scoring system from Ectopic Pregnancy**

1. Clinical Symptoms	Findings	Scoring
	Vaginal bleeding & Pain abdomen	
	a) No complaint	0
	b) Single Complaint	1
	c) Both complaints	2

2. Endometrial changes	A) Normal homogeneous appearance / Trilaminar appearance.	0
	B) Thickened / Decidual reaction / Pseudosac.	1
3. Corpus luteum	a) Corpus luteum and adnexal mass both seen separately	2
	b) only adnexal mass seen	1
	c) Only corpus luteum seen	0
4. Adnexal lesions	a) Not seen	0
	b) Anechoic lesion seen (Simple adnexal mass)	1
	c) Hypoechoic with Echogenic peripheral ring / Exophytic corpus luteum	2
	d) Hyperechoic / Heterogenous mass	3
5. Haemoperitoneum / Peritoneal fluid	a) No fluid	0
	b) Mild fluid	1
	c) Moderate to severe	2
Total Highest score	10	
Suspicion for Ectopic	> 5	
Possibility of Ruptured Ectopic	> 7	

**Case scenarios:**

**CASE 1:**

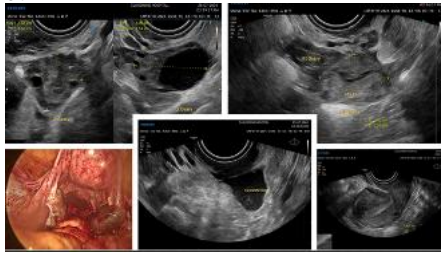
A 33 year old female patient came for pelvic scan in view of pain in lower abdomen and pelvis(score -1). There was no history of bleeding per vagina. She is 2 weeks 4 days according to her LMP.

Scan findings include Normal Endometrium(No intrauterine sac)(score -0), corpus luteal cyst in left ovary(score -2), hypoechoic adnexal cyst with thick echogenic peripheral rim adjacent to right ovary (score2) and mild fluid with internal echoes in pouch of douglas(score 1)

Findings	score
1.Pain in lower abdomen	1
2. Normal Endometrium	0
3. hypoechoic adnexal cyst with thick echogenic peripheral rim adjacent to right ovary	2
4.Mild fluid with internal echoes in POD	1
5Corpus luteum and adnexal mass both are seen separately	2
<b>TOTAL SCORE</b>	<b>6</b>

According to Ectopic Scoring System (ESS)described above, total score came as 6. So we suspected Ectopic and suggested Referral doctor to verify UPT status and to see for doubling of

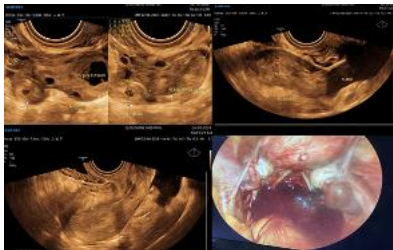
Beta HCG after 48 hrs. UPT came as positive and there was no doubling of Beta HCG. In the mean while, patient complained severe abdominal pain and posted for laparoscopy and ruptured tubal ectopic was confirmed and salpingectomy was performed.



**CASE 2**

A 28 year old female came for pelvis scan with complaints of Lower abdominal pain, Bleeding per vagina. Patient has UPT Positive status with Beta HCG value on the day of scan was 492 mIU/ml. Based on her LMP, her menstrual age was 6 weeks 1 day.

Findings	score
1.Pain in lower abdomen, vaginal bleed	2
2. Thickened Endometrium	1
3. Hypoechoic adnexal cyst with thick echogenic peripheral rim and illdefined heterogenous mass adjacent to right ovary	3
4.Mild to moderate fluid with internal echoes in POD	1
5. Corpus luteum and adnexal mass both are seen separately	2
<b>TOTAL SCORE</b>	<b>9</b>

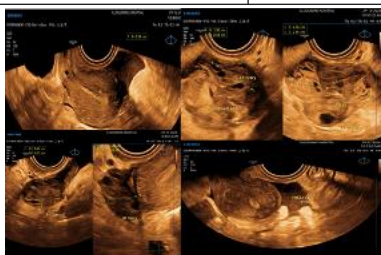

In view of high total score in our Ectopic scoring system, diagnosis of ruptured tubal ectopic was made. Patient was immediately posted for laparoscopy and ruptured tubal ectopic was confirmed and salpingectomy was performed.

**CASE 3**

A 31 year old female came for emergency scan in view of mild abdominal pain after 10 days of diagnosing unruptured Ectopic pregnancy with UPT positive status and medical management with methotrexate

Findings	score
1.Pain in lower abdomen	1
2. Normal Endometrium	0
3. Heterogenous complex mass adjacent to left ovary	3
4.Mild fluid with internal echoes in POD	1
5. only adnexal mass is seen.	1
<b>TOTAL SCORE</b>	<b>6</b>

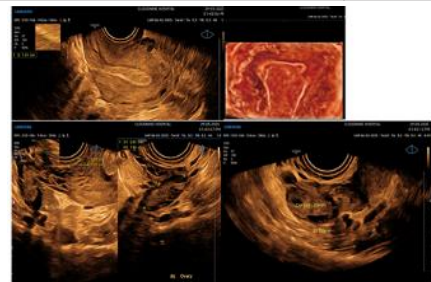


As the patient diagnosis has already been made, patient was immediately posted for surgery in view of severe pain abdomen. Intraoperatively diagnosis of ruptured left tubal ectopic was confirmed and salpingectomy was done.

**CASE 4**

A 33 year old female with UPT positive status and absent intrauterine gestational sac came for second opinion, as it was reported as unruptured ectopic pregnancy outside. Based on her LMP, her menstrual age was 7 weeks 2days at the time of scan.

Findings	score
1. No complaints	0
2. Normal Endometrium	0
3. No adnexal mass	0
4. Mild fluid with internal echoes in POD	0
5. only corpus luteum is seen in left ovary.	1
<b>TOTAL SCORE</b>	<b>1</b>



As the total score is less ie 1, Couple have been reassured and explained about the possible outcomes of pregnancy like progression of pregnancy (in case of early pregnancy with delayed ovulation) and failure of early pregnancy. Follow up scan after 2 weeks was suggested. After few days patient came with spotting per vagina and signs of early pregnancy failure. Similar type of cases are seen frequently and ectopic pregnancy has been excluded with the help of this scoring system.

**OUR EXPERIENCE**

Transvaginal pelvic sonography provides improved visualization of the endometrium, endometrial cavity, and gestational sac. A collection of blood and debris in the endometrium, also known as pseudosac can be seen in about 20% ectopic pregnancies. Adnexa are well depicted on transvaginal pelvic sonography. Pelvic sonography is performed in both sagittal and transverse planes, with both transabdominal and transvaginal approach. Extrauterine mass and free fluid in the pelvis are important clues. Imaging of paracolic gutters, perihepatic, and perisplenic region should be performed to quantify the amount of hemoperitoneum

On color Doppler images, hyper vascular ring with low impedance also referred as “Ring of Fire” in the ovary is not so helpful sign for us, as it is also seen with corpus luteal cyst where its incidence is more common than ectopic pregnancy. We haven't relied on both traditional signs like 'Ring of fire' and 'tubal ring' sign as they are causing many false positive results. Instead of taking single parameter into consideration, we found that Ectopic scoring system for tubal ectopic pregnancies made the diagnosis easier and less confusing.

In case of other Ectopic pregnancies, we incorporated 3D TVS in every early pregnancy to locate the gestational sac accurately and rule out interstitial, cervical, c-section scar pregnancies

**CONCLUSION**

We recommend Ectopic scoring system be to used for Urine Pregnancy Test Positive cases or cases with absent doubling of Beta-HCG with no Intrauterine gestational sac.

Ectopic scoring system helped us to reduce the false positive

rate and also to accurately diagnose in an easier way. The chances of ruptured ectopic were increased with ESS more than 7. In cases with score below 5 , mostly the outcome was failure of intrauterine pregnancy. In cases with score between 5 to 7, we have seen unruptured ectopic pregnancy.

#### REFERENCES

1. RadioGraphics October 2008 28(6):1661  
<https://pubs.rsna.org/doi/full/10.1148/rg.286085506> PMID - 18936028
2. Chanana C, Gupta N, Bansal I, Hooda K, Sharma P, Gupta M, Gandhi D, Kumar Y. Different
3. Sonographic Faces of Ectopic Pregnancy. J Clin Imaging Sci. 2017 Feb 20;7:6. doi: 10.4103/jcis.JCIS\_105\_16. PMID: 28299234; PMCID: PMC5341302.
4. Levine D. Ectopic pregnancy. Radiology. 2007 Nov;245(2):385-97. doi: 10.1148/radiol.2452061031. PMID: 17940301.
5. Perriera L, Reeves MF. Ultrasound criteria for diagnosis of early pregnancy failure and ectopic pregnancy. Semin Reprod Med. 2008 Sep;26(5):373-82. doi: 10.1055/s-0028- 1087103. Epub 2008 Sep 29. Erratum in: Semin Reprod Med. 2009 Jan;27(1):103. PMID: 18825605.