



ORIGINAL RESEARCH PAPER

Histopathology

HISTOPATHOLOGICAL SPECTRUM OF PSORIASIS - A RETROSPECTIVE STUDY FROM A TERTIARY CARE HOSPITAL IN WESTERN INDIA

KEY WORDS: Acanthosis, Auspitz sign, Histopathology, Munro microabscess, Psoriasis

Darshana Rajeev Pol	MBBS, 3rd year MD Pathology resident at GMERS Medical college & hospital, Gotri, Vadodara
Riya Visavadiya*	MBBS, MD Pathology, Senior resident at GMERS Medical college & hospital, Gotri, Vadodara*Corresponding Author
Dimple Hardik Darad	MBBS, MD Pathology, Professor HG at GMERS Medical college & hospital, Gotri, Vadodara

ABSTRACT

Background and Objectives: Psoriasis is a lifelong immune mediated skin disease associated with inflammation. Genetic predisposition has a significant role in psoriasis. The disease is usually easy to diagnose on clinical features alone; microscopic analysis of skin biopsy specimens is done to confirm the diagnosis. The objective of this study was to know the histopathological spectrum and incidence of age, sex, duration and distribution in various types of psoriasis. **Material and Methods:** A Retrospective study over a period of 6 years was carried out. 50 clinically diagnosed cases of psoriasis were taken into consideration. Skin biopsies were taken from these cases and histopathological examination was done. **Results and Discussion:** Maximum number of cases were in the age group of 21-30 years, males being more affected than females. The most common variant is psoriasis vulgaris. Lower limbs and back were most frequently affected. Among the microscopic findings, parakeratosis and acanthosis were observed and when present with elongation of rete ridges, dermal infiltration and vasodilation or perivascular lymphocytic infiltrate were likely to indicate psoriasis. Munro micro abscesses and spongiform pustules of Kogoj are diagnostic features of psoriasis and were seen in significant proportions. **Conclusion:** Diagnosis of psoriasis is made based on the clinical symptoms and signs with a correlation with histopathological features.

INTRODUCTION-

Psoriasis is a chronic, recurrent immune mediated inflammatory disorder of skin. Clinically characterized by erythematous papules and plaques covered by silvery-white scales over the extensor surfaces 1. In classic form of psoriasis, it is easy to diagnose with positive Auspitz sign and further confirmation by histopathological examination 2. Psoriasis has a genetic predisposition and is associated with HLA antigens and complement factors 3. Normally the maturation and shedding of skin cells take 10-30 days but the turnover is markedly increased in psoriasis 4. It has multiple phenotypically distinct types – guttate, pustular, plaque, inverse or erythrodermic. It is associated with other comorbidities such as cardiovascular diseases, hepatic diseases, psoriatic arthropathy and psychological diseases 5. The most common histopathological features observed are acanthosis, parakeratosis, Munro microabscess, spongiform pustules of Kogoj, perivascular and dermal infiltrates 6. The treatment aims at relieving the symptoms and improve the quality of life for the patients. Phototherapy reduces inflammation and cell proliferation rate and systemic therapy suppresses the immune response and inflammation 7.

MATERIAL & METHODS-

A Retrospective study of psoriasis lesions was carried out in the department of pathology at a tertiary care hospital from January 2018 to December 2024. 50 diagnosed cases of psoriasis, irrespective of age and gender were taken into consideration. Skin biopsies were taken from these cases. These were then fixed in 10% formalin, subjected to tissue processing followed by embedding in paraffin blocks, sectioning and finally stained with hematoxylin and eosin. Psoriasiform dermatitis cases were excluded. Age, sex, duration, site of lesions, type of psoriasis, and individual histopathological features of psoriatic lesions were noted from the recorded data and analyzed.

RESULTS-

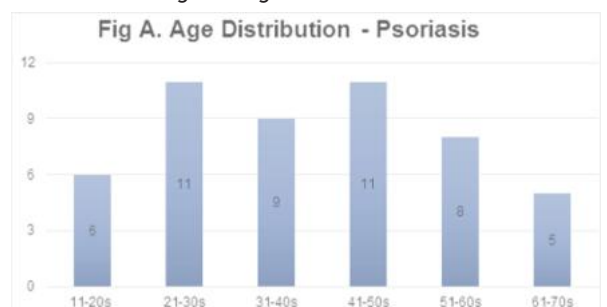
50 cases were diagnosed to have psoriasis in the study period. Maximum number of cases were in the age group of 21-30 years and 41-50 years i.e. 11 cases (22%) (Figure A). Least affected group was 61-70 years i.e. 5 cases (10%). 31 (62%) males and 19 (38%) females were diagnosed to have

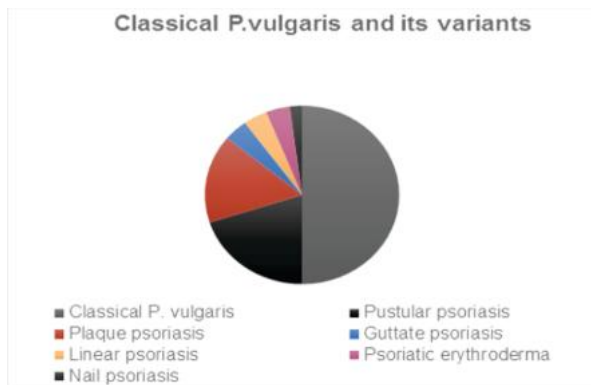
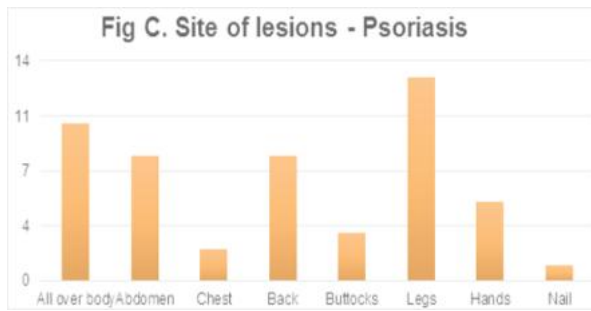
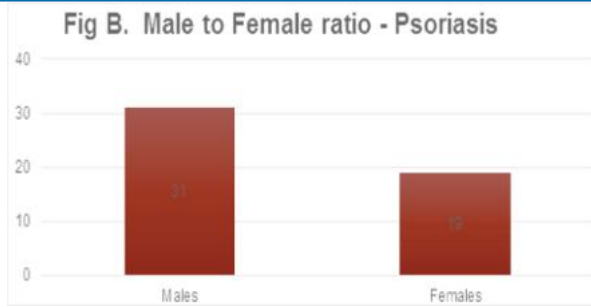
psoriasis with the male to female ratio being 1.63:1 (Figure B). The patients presented with erythematous papules and silvery scales with pruritis. The most common site was lower limbs with 13 cases (26%). The least common site was nails with 1 case (2%) (Figure C).

Out of the total 50 cases of psoriasis, 25 (50%) cases were diagnosed to be psoriasis vulgaris, 10 (20%) cases were pustular psoriasis, 8 (16%) cases were diagnosed to be plaque psoriasis, 2 (4%) cases each of guttate psoriasis, linear psoriasis, psoriatic erythroderma and 1 (2%) case of nail psoriasis (Figure D).

Among the various microscopic parameters studied, parakeratosis is seen in 36 (72%) cases, acanthosis in 32 (64%) cases, hyperkeratosis in 20 (40%), hypogranulosis and suprapapillary thinning in 10 (20%) cases. Munro microabscesses in 17 (34%) cases, elongated rete ridges in 33 (66%) and dermal inflammation in 39 (78%) cases.

Table 1 gives a comparison of various microscopic parameters in this study with various other studies. From the table, acanthosis and parakeratosis are seen in most of the cases. When present with features like hypogranulosis, elongation of rete ridges, dermal inflammation and vascular change like dilated vessels or perivascular lymphocytic infiltrate are likely to indicate psoriasis. Munro microabscess and spongiform pustules of Kogoj which are diagnostic features of psoriasis were also seen in significant proportion, further confirming the diagnosis.





Non specific findings	12	-	5	-	-
-----------------------	----	---	---	---	---

DISCUSSION-

Psoriasis is an increasingly common papulosquamous disorder. The worldwide prevalence of psoriasis is 2-3%. Although the disease has higher prevalence in polar regions [12]. Prevalence among Asian populations is also lower. Among Indian studies, as per Raghuveer C et al., 1.2% of their outpatients had psoriasis [13].

Pathogenesis is a combination of genetic, immunological and environmental factors. The PSORS1 gene has high percentage of familial cases. Exaggerated activation of T lymphocytes leads to release of inflammatory cytokines such as TNF-alpha, IL-17, IL-23 and IL-22 triggering a cascade of inflammatory events and promote increased proliferation of keratinocytes. Keratinocytes in turn produce more inflammatory cytokines, creating a self-amplifying cycle of inflammation and cell proliferation [7].

Mean age of presentation is between 21-30 years [9]. In the present study, maximum number of cases were in the age group of 21-30 years and 41-50 years (22%). Least affected was the age group of 61-70 years (10%). This was similar to the findings of Karumbaiah KP et al., who also found the age group of 21-40 years to be most affected [11]. Few studies show bimodal age distribution. This may be because psoriasis can be divided into 2 types - type 1 and 2 based on age of onset [14]. But this was not found in our study.

As per Karumbaiah KP et al., the male to female ratio of incidence was 2.33:1 and as per Hosamane S et al., the male to female ratio of incidence was 2:1 [10,11]. In our study, 62% males and 38% females were diagnosed to have psoriasis with the male to female ratio being 1.63:1. The lower incidence in females is due to being less attentive to health and occurrence of psoriasis over covered parts [13].

The presentation of psoriasis comprises of pruritis which is the most common symptom along with burning sensation, pain and bleeding. The lesions are commonly circular, well defined, red papules or plaques with grey or silvery white dry scales usually on the extensor surfaces [9]. Auspitz sign is usually positive characterized by pinpoint bleeding points on removal of silvery scales. In the cases of psoriasis that we encountered, the most common site was legs where they were seen in 26% cases, followed by back and abdomen where they were seen in 16% cases respectively. The least common sites were nail and chest. Other studies however had different observations. Waghmare R et al., reported, back to be the most affected (33%), followed by upper limbs, lower limbs and abdomen [9]. Few other studies like Karumbaiah KP et al., and Raghuveer C et al., showed lesions most commonly on extremities, trunk followed by scalp and arm [11,13].

Clinically, psoriasis can be of various types. Out of total 50 cases studied, different variants were 50% - psoriasis vulgaris, 20% - pustular psoriasis, 16% - plaque psoriasis, 4% - guttate psoriasis, linear psoriasis and psoriatic erythroderma each and 2% - nail psoriasis. Other studies like, Waghmare R et al., also reported similar incidence of various types [9].

CONCLUSION-

Psoriasis is a chronic dermatological disorder with remissions and exacerbations. Histopathological confirmation serves as a tool and rules out the lesions that mimic other psoriasiform diseases. Hence, it is concluded that classical P.vulgaris is the most common type of psoriasis and different clinico-morphological patterns are based on variable histopathological spectrum of disease.

REFERENCES-

1. Anupama Y G, Patil SB. A retrospective clinicohistopathological study of

Table-1: Comparison of microscopic parameters of psoriasis in various studies

Parameters - Microscopy	Present study (%)	Negrutiu M et al., (%) [8]	Waghmare R et al., (%) [9]	Hosamane S et al., (%) [10]	Karumbaiah KP et al., (%) [11]
Acanthosis	64	91.7	93	90.47	86.36
Parakeratosis	72	100	84	61.9	72.72
Hyperkeratosis	40	50	32	28.57	77.27
Orthokeratosis	4	-	11	-	-
Hypogranulosis	20	66.7	61	19.04	22.72
Munro Microabscess	34	75	61	26.19	22.72
Spongiform Pustules	12	-	34	11.9	4.54
Elongated Rete ridges	66	66.7	71	-	-
Suprapapillary dermal thinning	20	-	45	35.71	40.90
Dermis					
Dermal inflammation	78	100	100	66.66	81.81
Vascular changes	50	66.7	64	14.28	86.36
Other changes					
Focal spongiosis	32	-	-	-	-
Neutrophil exocytosis	24	-	-	-	-
Psoriasiform hyperplasia	4	100	-	90.47	72.72

- psoriasis. *IP Indian J Clin Exp Dermatol* 2020;6(3):222-226.
2. Aggarwal M, Krishnan K, Seth S. Histopathological study of psoriasis: A retrospective study of a rural tertiary care center in Faridabad. *IJIRT*. 2025 April; Vol 11 Issue 11
 3. Dogra S, Yadav S. Psoriasis in India: Prevalence and pattern. *Indian J Dermatol Venereol Leprol* 2010;76:595-601.
 4. Khushi Prajapati, Dr. Shweta Paroha, & Dr. Pragnesh Patani. (2024). A SYSTEMATIC REVIEW OF TYPES, SYMPTOMS AND TREATMENT OF PSORIASIS. *Journal of Population Therapeutics and Clinical Pharmacology*, 31(11), 1218-1229.
 5. Raharja A, Mahil SK, Barker JN. Psoriasis: a brief overview. *ClinMed (Lond)*. 2021 May;21(3):170-173. Doi: 10.7861/clinmed.2021-0257. PMID: 34001566; PMCID: PMC8140694.
 6. Anaba, E. L. Dawodu, O. O., & Arabambi, B. (2022). Histopathological Analysis of Psoriasis. *Orient Journal of Medicine*, 34(3-4), 91-96.
 7. Riojas ME. Psoriasis treatment: a literature review. *Int J Res Dermatol* 2023;9:314-7
 8. Negrutiu M, Danescu S, Popa T, Focsan M, Vesa SC, Szasz F, Baican A. Imaging Approach in the Diagnostics and Evaluation of the Psoriasis Plaque: A Preliminary Study and Literature Review. *Diagnostics (Basel)*. 2024 May 7;14(10):969. doi: 10.3390/diagnostics14100969. PMID: 38786267; PMCID: PMC11120603.
 9. Waghmare R. Histopathological Study of Psoriasis: A Prospective Cum Retrospective Study at a Tertiary Care Centre. *Saudi Journal of Pathology and Microbiology*. 2020; doi:10.36348/SJPM.2020.V05I05.002
 10. Hosamane S, Pai M, Philipose TR, Nayarmoole U. Clinicopathological Study of Non-Infectious Erythematous Papulosquamous Skin Diseases. *J Clin Diagn Res*. 2016 Jun;10(6):EC19-22. Doi: 10.7860/JCDR/2016/18607.8029. Epub 2016 Jun 1. PMID: 27504295; PMCID: PMC4963655.
 11. Karumbaiah, K. P., Anjum, A., Dangar, K., Mallikarjun, M., & Kariappa, T. M. (2014). A Clinicopathological study of Psoriasis. *Scholars J Appl Med Sci*, 2, 298-302.
 12. Dogra S, Mahajan R. Psoriasis: Epidemiology, clinical features, comorbidities, and clinical scoring. *Indian Dermatol Online J* 2016;7:471-80.
 13. Raghuvver, C., Shivanand, D. R., & Rajashekar, N. (2015). A clinico-histopathological study of psoriasis. *Int J Sci Stud*, 3, 176-9.
 14. Nair PA, Badri T. Psoriasis. [Updated 2023 Apr 3]. In: Stat Pearls [Internet]. Treasure Island (FL): Stat Pearls Publishing; 2025 Jan